

# EVALUATION OF OPTIC DISC DRUSEN USING MODERN IMAGING PARACLINICAL METHODS

Březík Michal<sup>1,2</sup>, Kopecný Adam<sup>2,3</sup>, Chrapek Oldřich<sup>1,4</sup>,  
Tímkoří Juraj<sup>2,3</sup>, Němčanský Jan<sup>2,3</sup>

<sup>1</sup>Clinic of Ophthalmology, Faculty of Medicine, Masaryk University, Brno, Czech Republic

<sup>2</sup>Clinic of Ophthalmology, University Hospital Ostrava, Czech Republic

<sup>3</sup>Faculty of Medicine, Department of Craniofacial Surgery, University of Ostrava, Czech Republic

<sup>4</sup>Clinic of Ophthalmology, University Hospital Brno, Czech Republic

*The authors of the study declare that no conflict of interests exists in the compilation, theme and subsequent publication of this professional communication, and that it is not supported by any pharmaceuticals company. The study has not been submitted to any other journal.*

Submitted to the editorial board: May 13, 2024

Accepted for publication: July 10, 2024

Available on-line: August 25, 2024



MUDr. Michal Březík, FEBO  
Oční klinika Fakultní nemocnice  
Ostrava  
17. listopadu 1790/5  
708 52 Ostrava – Poruba  
E-mail: michal.brezik@fno.cz

## SUMMARY

**Purpose:** To analyze patients with optic disc drusen (ODD), with emphasis on modern diagnostics.

**Materials and Methods:** Research of the literature was conducted, together with a retrospective statistical analysis of patients with ODD. The group included individuals with ODD diagnosed using at least one of the following (ultrasound – USG, optical coherence tomography – OCT, fundus autofluorescence – FAF).

**Results:** The group consisted of 12 patients (23 eyes), 7 women and 5 men. The mean age was 25 years. The mean observation period was 73 months. In total, 11 patients (22 eyes) had a bilateral finding and 1 patient (1 eye) had a unilateral finding. The mean age was 25 years. Buried drusen were confirmed in 69.6% of cases (8 patients, 16 eyes), superficial drusen were confirmed in 30.4% of cases (4 patients, 7 eyes). Mean best corrected visual acuity (BCVA) and mean intraocular pressure were stable over time (BCVA  $p = 0.236$ , IOP  $p = 0.855$ ). The aforementioned diagnostic methods proved to be equally effective ( $p = 0.768$ ). In 11 patients (21 eyes) a depression of the retinal nerve fiber layer (RNFL) was recorded. We found a statistically significant decrease of the RNFL over time in reference to the normative database in the superior temporal ( $p = 0.015$ ), temporal ( $p = 0.026$ ) and nasal segments ( $p = 0.011$ ). After separation of superficial and buried drusen the same significant change was found in nasal segment in superficial drusen ( $p = 0.031$ ). We found no statistically significant difference over time between superficial and buried drusen ( $p = 0.109$ – $0.999$  for individual segments).

**Conclusion:** ODD are common and visual functions remain stable. Their presence can be confirmed using modern paraclinical methods.

**Key words:** optic disc drusen, Optical coherence tomography, Ultrasound, Fundus autofluorescence

Čes. a slov. Oftal., 80, 2024, No. 6, p. 324–330

## INTRODUCTION

Optic disc drusen (ODD) are an acellular deposit which is present in the prelaminar part of the optic nerve in up to 2.4% of the population [1,2]. They are composed of amino acids, nucleic acids, mucopolysaccharides and calcareous deposits [1,2]. The pathophysiology is not clear, but a combination of developmental dysplasia, genetic predisposition and malfunction of the axonal metabolism is assumed [2]. According to certain studies they occur more frequently in individuals of Caucasian racial origin [3–7]. In the available literature there is a slightly higher proportion of women in the cohorts [8,9]. ODD mostly occur bilaterally

[8,10]. In general they can be divided according to localization into superficial (A) and buried (B) (Figure 1). Another option is to divide them according to the degree of calcification into calcified and uncalcified. They are usually a chance finding, nevertheless their presence may affect visual functions. Causal treatment is not known, although in certain situations local and surgical therapy may be indicated [11–14].

## MATERIAL AND METHODS

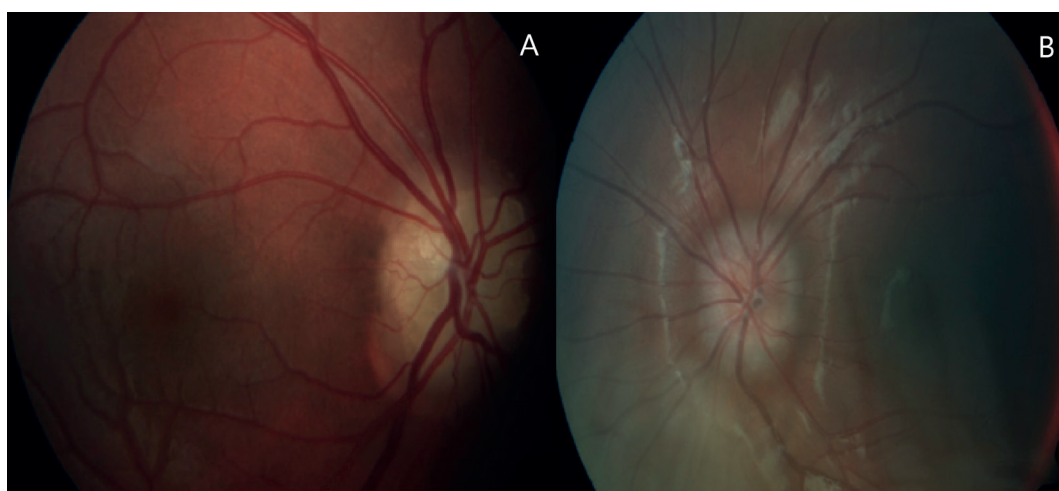
A systematic overview of the literature was searched in the databases PubMed and Web of Science Core Collection, using the key words optic disc drusen (ODD), optical

coherence tomography (OCT), ultrasonography (USG) and fundus autofluorescence (FAF). This was followed by a retrospective analysis of all the patients treated at the Department of Ophthalmology at the University Hospital in Ostrava for suspected optic disc drusen in the period from January 1, 2016, to September 30, 2020. All patients in whom ODD was diagnosed using at least one of the paraclinical examination methods (USG, OCT, FAF) were included in the cohort. A comprehensive eye examination was conducted on all patients, incorporating assessment of best corrected visual acuity (BCVA) on Snellen charts (Medico – OTS, s.r.o., Hradec Králové, CZ), intraocular pressure (IOP) with the aid of the contour tonometer Pascal (Ziemer Group, Port, Switzerland), examination of the anterior and posterior segment of the eye on a slit lamp CSO – SL 9900 (CSO, Scandicci, Italy), and of the visual field with the aid of the computer perimeter OCTOPUS 900 (Haag – Streit Group, Köniz, Switzerland). The presence of ODD was documented with the aid of a fundus camera Zeiss FF450+IR (Carl Zeiss Meditec AG, Jena, Germany), autofluorescence mode of the device OCT Spectralis (Heidelberg Engineering GmbH, Heidelberg, Germany) and an ultrasonic B-scan Keeler Accutome Connect (Keeler, Malvern, USA). Structural changes in the prelaminar part of the optic nerve were evaluated in the form of examining the thickness of the retinal nerve fiber layer (RNFL) on the instrument OCT Spectralis. Division of drusen into superficial and buried was based on a biomicroscopic examination of the fundus, in which typical yellowish-pink deposits on the surface of the optic nerve disc were indicated as superficial drusen, while in the case of buried drusen the disc was only of effaced edges imitating papilledema (following its prior exclusion). Ultrasonic evidence required examination by a probe with a frequency of 12 MHz, in which detection of hyperechogenicity in the prelaminar part of the optic nerve with or without acoustic shadow, which persisted upon a low gain regulator of the instrument (0–10 dB) was acknowledged as evidence [15]. Evidence of drusen on autofluorescence was based on a finding of rounded

or oval hyperautofluorescent deposits on the papilla [16]. Evidence of drusen on OCT was based on the following criteria: finding of cavitation with hyporeflective center and more reflective encasement, reflectivity most pronounced in the anterior section, location of the deposit process in front of the lamina cribrosa of the optic nerve (14). RNFL thickness was measured on an OCT instrument using standard sectors (naso-superior – NS, nasal – N, naso-inferior – NI, temporo-inferior – TI, temporal – T, temporo-superior – TS) and configuration of a normative database for the Caucasian race. Perimetric examination was considered reliable if errors of fixation, false positive and false negative responses were less than 15%. The evaluated numerical variables were age, BCVA, IOP and RNFL. The numerical variables were described with the aid of descriptive statistical methods (M – median, Min / Max – minimum and maximum value of variables, IQR – interquartile range). The categorical variables were described with the aid of absolute and relative frequency (%). A comparison of the observed variables with normative values was performed with the aid of a paired Wilcoxon Signed Rank test. A Mann-Whitney test was used for comparison of the observed variables between the groups according to the type of drusen and variables of the initial and final examination. The success rate of identification of the used diagnostic methods was calculated with the aid of a Fisher exact test. The level of statistical significance was set at 0.05, and all analyses were conducted within the software R (version 4.3.1, The R Foundation for Statistical Computing, Vienna, Austria).

## RESULTS

During the monitored period we recorded the presence of ODD in 12 patients (23 eyes), of whom 7 (58.3%) were women and 5 (41.7%) were men. The median age of the patients was 25 years (IQR 6–65 years), with no statistically significant difference in the mean age value of men and women (Mann-Whitney test,  $p = 0.464$ ). The mean observation period was 73 months (interval 19–103 months). In



**Figure 1.** Color picture of (A) superficial and (B) buried optic disc drusen

11 patients (22 eyes) this concerned a bilateral finding, in 1 case (1 eye) unilateral. Buried optic disc drusen were determined in 8 patients (16 eyes, 69.6%), and superficial drusen in 4 patients (7 eyes, 30.4%). The mean value of BCVA both at baseline and at the end of the monitored period was 1.0 (interval 0.1–1.0 at baseline examination, interval 0.2–1.0 at final examination,  $p = 0.236$ ). The mean value of IOP was 18.0 mmHg at the baseline examination (interval 12–28 mmHg) and 17.0 mmHg at the final examination (interval 9–24 mmHg). The difference between the mean value of IOP at the baseline and final examination was not statistically significant ( $p = 0.855$ ). The effectiveness of identification of optic disc drusen with the aid of paraclinical examinations is presented in summary in Table 1. All these examinations are of equal value with regard to diagnosis (Fisher's exact test,  $p = 0.768$ ). In 11 patients (21 eyes) a decrease of the RNFL was recorded. A comparison of the baseline and final data of the RNFL, superficial drusen, buried drusen and also of the entire cohort with the normative database is presented in Table 2. A comparison of the sectors of superficial and buried drusen at the baseline

and final examination is presented in Table 3. A perimetric examination was performed on all eyes with the following distribution of types of blind spots: 1) 14 eyes non-specific scotomization, 2) 8 eyes inferior arcuate scotoma, 3) 1 eye with physiological scope of visual field.

## DISCUSSION

The median age in our cohort at the time of determination of the diagnosis was 25 years. According to some studies, progression of the size of drusen after 30 years of age is minimal or nonexistent [3]. In our cohort, the mean values of BCVA and IOP were stable throughout the period of observation. Results supporting our observation can be found in the literature [16]. In our cohort 16 eyes (69.6%) manifested buried drusen, the remainder (30.4%) were superficial drusen. This proportion does not correspond with other studies, in which the authors describe a predominance of the superficial variant [8,17].

Ultrasonographic examination is a regularly available diagnostic method for detection of ODD, but it is not capable of imaging as yet uncalcified drusen. Calcification usually occurs at around the 8<sup>th</sup> year of life [17]. Superficial drusen are displayed with the aid of USG in Figure 2.

Similarly as in our cohort, according to a number of other sources also FAF is an examination method of equal value to USG [3,18]. The excitation focuses of the papilla in the case of FAF are calcificates and mitochondrial porphyrins [19]. Figure 3 shows superficial (A) and buried (B) drusen respectively imaged using FAF. Some studies state that the sensitivity of FAF in the case of buried drusen is approximately half that of USG, though with regard to superficial drusen the methods are of equal value [3,18].

**Table 1.** The comparison of the effectivity of paraclinical methods

	n	Accuracy (%)
FAF	21/23	91.3%
USG	22/23	95.7%
OCT	23/23	100.0%
P-value of the Fisher's exact test		0.768

FAF – fundus autofluorescence, USG – ultrasound, OCT – optical coherence tomography

**Table 2.** The comparison of the RNFL (retinal nerve fiber layer) data of our group with normative database. The statistically significant values in bold

Segment	Normative values	Total (n = 23)		Superficial optic disc drusen (n = 7)		Buried optic disc drusen (n = 16)	
		Median (Min; Max)	p	Median (Min; Max)	p	Median (Min; Max)	p
1. examination							
TS	138	116 (45; 301)	0.062	76 (45; 158)	0.075	122 (51; 301)	0.293
NS	102	93 (19; 295)	0.543	74 (43; 112)	0.078	96 (19; 295)	0.796
TI	147	154 (35; 228)	0.903	66 (35; 228)	0.236	155 (95; 205)	0.423
NI	108	111 (42; 252)	0.963	88 (59; 160)	0.578	115 (42; 252)	0.623
T	78	72 (46; 97)	0.104	64 (46; 85)	0.075	73 (49; 97)	0.501
N	72	61 (20; 185)	0.153	54 (27; 73)	0.059	63 (20; 185)	0.632
2. examination							
TS	138	88 (35; 361)	0.015	77 (43; 104)	0.016	116 (35; 361)	0.201
NS	102	73 (17; 338)	0.092	70 (38; 102)	0.036	89 (17; 338)	0.570
TI	147	138 (33; 190)	0.055	70 (35; 171)	0.078	147 (33; 190)	0.379
NI	108	89 (28; 186)	0.100	79 (61; 175)	0.297	103 (28; 186)	0.338
T	78	67 (42; 101)	0.026	61 (42; 90)	0.075	69 (48; 101)	0.187
N	72	47 (15; 208)	0.011	36 (27; 83)	0.031	52 (15; 208)	0.083

P-values were obtained with the one-sample Wilcoxon test (two-tailed).

TS – superior temporal, NS superior nasal, TI – inferior temporal, NI – inferior nasal, T – temporal, N – nasal

Cross-sections through the optic nerve disc with the aid of OCT are currently considered the most detailed and most sensitive diagnostic method for ODD, although this method is more demanding for interpretation of the findings [3,17]. They enable the evaluation of both superficial and buried drusen, calcified and uncalcified. Upon evaluation using OCT it is possible to start out from a number of basic characteristics of drusen [17]. They are always located in the prelaminar part of the optic nerve, mostly concerning cavitations with a hyporeflective center and more reflective encasement, in which reflectivity is most pronounced in the anterior section. A pre-stage of drusen may be hyperreflective horizontal strips [17]. A typical OCT finding of superficial (A) and buried (B, C) optic disc drusen is presented in summary in Figure 4.

RNFL thickness is an important parameter both of drusen themselves and of ocular pathologies associated with them [13]. In our cohort a decrease of RNFL curvature was recorded, which corresponds with the literature [10,14]. The same sources also refer to a minimal difference in decrease of the RNFL between superficial and buried drusen. We recorded a statistically significant decrease of curvature over time with regard to the normative database in the segments TS, T and N, nevertheless after division of the data into superficial and buried drusen we recorded a statistically significant decrease only in segment N for superficial drusen. We did not record a statistically significant difference in the change of RNFL over time between superficial and buried drusen.

Fluorescence angiography was not used in our cohort

**Table 3.** The comparison of first and last RNFL (retinal nerve fiber layer) segment data in superficial and buried drusen. The difference in time between the groups wasn't clinically significant

Segment	Median (Min; Max)		p
	Superficial optic disc drusen (n = 7)	Buried optic disc drusen (n = 16)	
TS			
1. examination	76 (45; 158)	122 (51; 301)	0.270
2. examination	77 (43; 104)	116 (35; 361)	0.154
Difference	-2 (-74; 7)	-5 (-79; 75)	0.616
NS			
1. examination	74 (43; 112)	96 (19; 295)	0.332
2. examination	70 (38; 102)	89 (17; 338)	0.285
Difference	-1 (-57; 5)	-3 (-263; 67)	0.664
TI			
1. examination	66 (35; 228)	155 (95; 205)	0.300
2. examination	70 (35; 171)	147 (33; 190)	0.118
Difference	0 (-89; 16)	-5 (-81; 8)	0.547
NI			
1. examination	88 (59; 160)	115 (42; 252)	0.713
2. examination	79 (61; 175)	103 (28; 186)	0.639
Difference	-2 (-61; 15)	-4 (-89; 18)	0.547
T			
1. examination	64 (46; 85)	73 (49; 97)	0.160
2. examination	61 (42; 90)	69 (48; 101)	0.181
Difference	-3 (-6; 9)	-1 (-21; 8)	0.418
N			
1. examination	54 (27; 73)	63 (20; 185)	0.350
2. examination	36 (27; 83)	52 (15; 208)	0.688
Difference	-3 (-41; 44)	-3 (-170; 44)	>0.999
G			
1. examination	65 (47; 115)	100 (60; 190)	0.192
2. examination	60 (47; 110)	83 (32; 195)	0.109
Difference	-3 (-47; 10)	-3 (-71; 6)	0.738

P-values were obtained with the Mann-Whitney test.

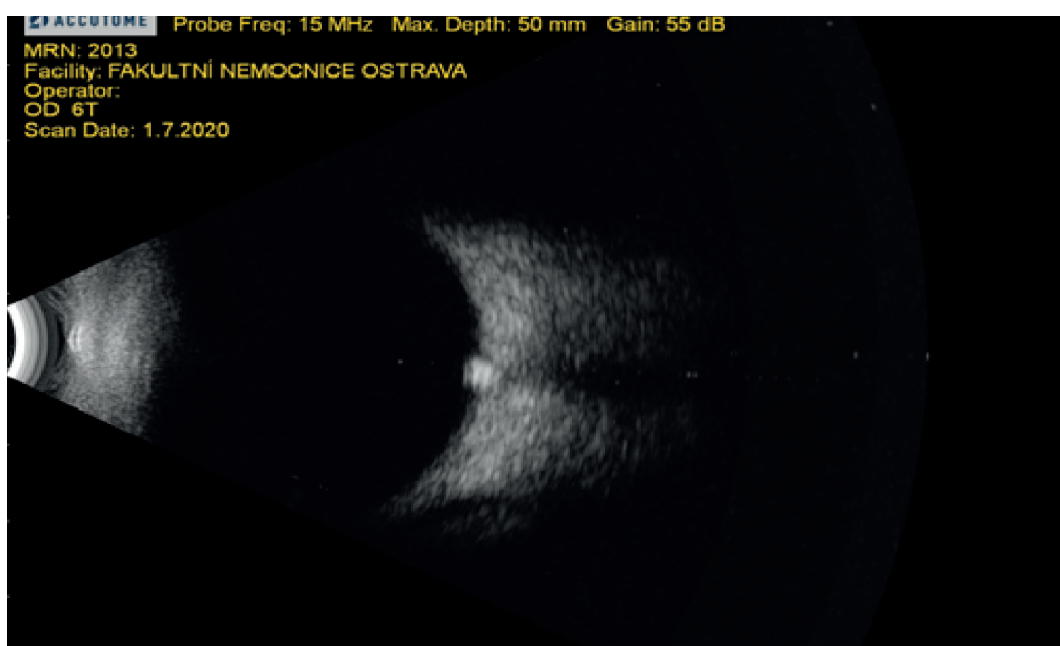
TS – superior temporal, NS superior nasal, TI – inferior temporal, NI – inferior nasal, T – temporal, N – nasal



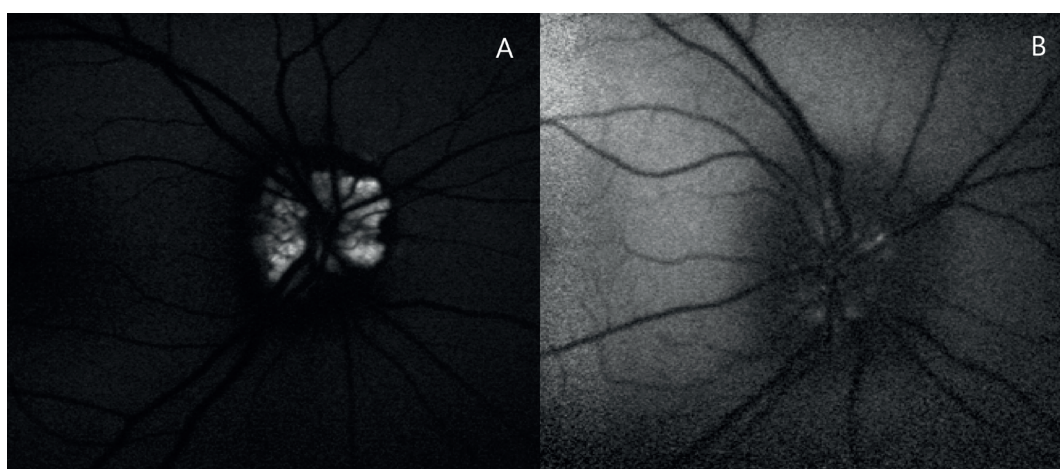
but may be useful in differentiating between edema of the optic nerve disc and pseudopapilledema. Perimetry should be performed once per year. Morphological monitoring is ideally done on OCT [3,8,17]. In our cohort we did not record any statistically significant difference between the success rates of demonstrating ODD using the above-stated paraclinical imaging methods. Although ODD are generally viewed as impossible to influence by therapy, in the literature surgical procedures are described with the objective of improving visual acuity and the scope of the visual field. These typically start out from the assumption of the presence of compartment syndrome upon a background of ODD, the consequence of which is compressive neuropathy. Some authors have performed extraction of drusen by means of pars plana vitrectomy, although without

any positive influence on central visual acuity [20,21]. The Czech authors Jirásková and Rozsival performed decompression of the optics with the aid of surgery on the nerve encasements, with a good effect on visual acuity [11–13].

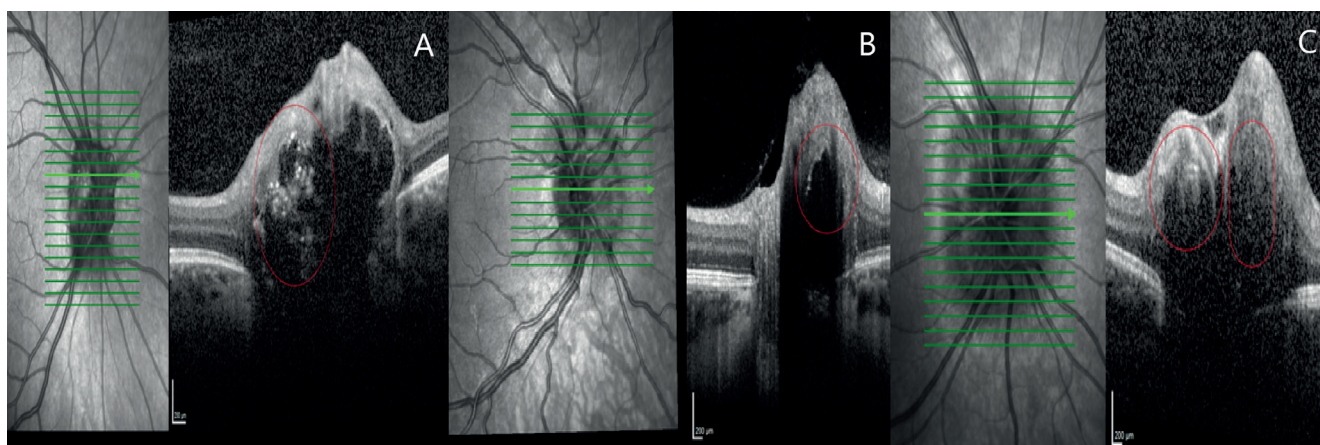
Some authors associate drusen with higher IOP [14,16,23–26], while others place them within a context together with blind spots of the visual field and a decrease of the RNFL [22]. The incidence of glaucoma has also been observed in families with familial optic drusen [23]. A significantly higher incidence of glaucoma was recorded in these families, specifically 20.7% [24]. Decrease of RNFL curvature is a questionable diagnostic parameter for ODD, and similarly the correlation of glaucoma pathognomy with ODD is relatively unconvincing [16]. In our cohort we recorded a decrease of



**Figure 2.** Calcified optic disc drusen seen on ultrasound



**Figure 3.** Autofluorescence of the optic disc with (A) superficial and (B) buried drusen



**Figure 4.** Optic disc drusen on OCT (optical coherence tomography), superficial optic disc drusen (A) with hyporeflective centre and hyperreflective coating, (B, C) buried optic disc drusen with hyporeflective centre and hyperreflective anterior coating causing shadowing and imitating edema, all encircled in red

thickness of the nerve fibers on OCT in 11 patients (21 eyes). In the literature no consensus exists on whether anti-glaucoma therapy should be used by patients with uncomplicated presence of drusen, with presence of drusen and progressive decrease of RNFL over time, or only by patients in whom glaucoma is diagnosed. There is also no description of a group of pharmaceuticals within the framework of anti-glaucomatous agents which would be the unequivocal first choice in the case of optic disc drusen.

In our cohort the only complication to be determined was the above-mentioned atrophic of the RNFL. This is the most common complication of ODD, and the finding therefore corresponds with the literature [3,8,17]. Other frequently described complications of ODD include non-arteritic anterior ischemic optic neuropathy [3,8,24], though bilaterality is not described more often [3]. A more frequent incidence of venous and arterial occlusions is also described, as well as more frequent incidence of peripapillary CNV (choroidal neovascularization) and subneuroretinal hemorrhage [3]. Other complications of optic disc drusen to be described include central serous chorio-

retinopathy and papillopathy with significant deterioration of vision [25].

## CONCLUSION

ODD are common within the Caucasian population. In most cases this concerns bilateral finding without symptoms, in which BCVA remains stable. In some cases they cause changes of the visual field. Besides biomicroscopy, today we use paraclinical examinations in diagnosis (USG, OCT, FAF), in which at our center we choose USG as the primary method due to the relatively simple interpretation of the results. However, OCT appears to be a more sensitive method, among other factors with regard to the possibility of more detailed imaging of the optic nerve disc. However, statistically all the above-mentioned examination methods are of equal value with regard to the diagnosis of ODD. If complications appear, this most frequently concerns atrophy of the RNFL, which may be of a progressive character. No causal treatment of drusen is known to date. Local therapy using anti-glaucomatous agents is controversial, surgical therapy is possible upon careful consideration of the degree of risk regarding the potential benefit of the operation.

## REFERENCES

- Friedman AH, Beckerman B, Gold DH, Walsh JB, Gartner S. Drusen of the optic disc. *Surv Ophthalmol.* 1977;21(5):375-390.
- Tso MO. Pathology and pathogenesis of drusen of the optic nerve-head. *Ophthalmology.* 1981;88(10):1066-1080.
- Palmer E, Gale J, Crowston JG, Wells AP. Optic Nerve Head Drusen: An Update. *Neuro-ophthalmology.* 2018;42(6):367-384.
- Thurtell MJ, Biousse V, Bruce BB, Newman NJ. Optic nerve head drusen in black patients. *J Neuroophthalmol.* 2012;32(1):13-16.
- Rosenberg MA, Savino PJ, Glaser JS. A clinical analysis of pseudopapilledema. I. Population, laterality, acuity, refractive error, ophthalmoscopic characteristics, and coincident disease. *Arch Ophthalmol.* 1979;97(1):65-70.
- You QS, Xu L, Wang YX, Jonas JB. Prevalence of optic disc drusen in an adult Chinese population: the Beijing Eye Study. *Acta Ophthalmol.* 2009;87(2):227-228.
- Mansour AM, Hamed LM. Racial variation of optic nerve diseases. *Neuro-ophthalmology.* 1991;11(6):319-323.
- Štrofová H, Jarošová A. Drúzy papily zrakového nervu a jejich komplikace [Optic Disc Drusen and their Complications]. *Cesk Slov Oftalmol.* 2016;72(1):298-308. Czech.
- Obuchowska I, Mariak Z. Zaburzenia pola widzenia w druzach tarczy nerwu wzrokowego [Visual field defects in the optic disc drusen]. *Klin Oczna.* 2008;110(10-12):357-360. Polish.
- Nentwich MM, Maertz J, Rudolph G. Drusenpappile – ein Überblick über medizinhistorische und aktuelle Aspekte [Optic Disc Drusen: Historical and Up-To-Date Aspects]. *Klin Monbl Augenheilkd.* 2016;232(3):257-265. German.
- Jirásková N, Rozsival P. Dekomprese obalů zrakového nervu [Decompression of the optic nerve sheath]. *Cesk Oftalmol.*

- 1995;51(4):254-257. Czech.
12. Jirásková N, Rozsival P. Dekomprese obalů zrakového nervu – výsledky prvních 37 operovaných očí [Decompression of the optic nerve sheath-results in the first 37 operated eyes]. *Cesk Slov Oftalmol.* 1996;52(5):297-307. Czech.
13. Jirásková N, Rozsival P. Výsledky 62 dekompresí obalů zrakového nervu [Results of 62 optic nerve sheath decompressions]. *Cesk Slov Oftalmol.* 1999;55(3):136-144. Czech.
14. Grippio TM, Shihadeh WA, Schargus M, et al. Optic nerve head drusen and visual field loss in normotensive and hypertensive eyes. *J Glaucoma.* 2008;17(2):100-104.
15. Nolan KW, Lee MS, Jalalizadeh RA, Firl KC, Van Stavern GP, McClelland CM. Optic Nerve Head Drusen: The Relationship Between Intraocular Pressure and Optic Nerve Structure and Function. *J Neuroophthalmol.* 2018;38(2):147-150.
16. Tuğcu B, Özdemir H. Optik disk drusenleri Tanisinda Görüntüleme Yöntemleri [Imaging Methods in the Diagnosis of Optic Disc Drusen]. *Türk J Ophthalmol.* 2016;46(5):232-236. Turkish.
17. Hamann S, Malmqvist L, Costello F. Optic disc drusen: understanding an old problem from a new perspective. *Acta Ophthalmol.* 2018;96(7):673-684.
18. Kurz-Levin MM, Landau K. A comparison of imaging techniques for diagnosing drusen of the optic nerve head. *Arch Ophthalmol.* 1999;117(8):1045-1049.
19. Denniston AKO, Murray PI. *Oxford Handbook of Ophthalmology.* 3rd ed. Oxford (England): Oxford University Press; 2014. Chapter 2, Investigations and their interpretation; p. 63.
20. Pfriem M, Hoerauf H. Unsuccessful surgical excision of optic nerve drusen. *Graefes Arch Clin Exp Ophthalmol.* 2011;249(10):1583-1585.
21. Kapur R, Pulido JS, Abraham JL, Sharma M, Buerk B, Edward DP. Histologic findings after surgical excision of optic nerve head drusen. *Retina.* 2008;28(1):143-146.
22. Roh S, Noecker RJ, Schuman JS. Evaluation of coexisting optic nerve head drusen and glaucoma with optical coherence tomography. *Ophthalmology.* 1997;104(7):1138-1144.
23. Gramer G, Gramer E, Weisschuh N. Optic Disc Drusen and Family History of Glaucoma-Results of a Patient-directed Survey. *J Glaucoma.* 2017;26(10):940-946.
24. Auw-Haendrich C, Staubach F, Witschel H. Optic disk drusen. *Surv Ophthalmol.* 2002;47(6):515-532.
25. Suelves AM, Francés-Muñoz E, Gallego-Pinazo R, et al. Central serous papillopathy by optic nerve head drusen. *Clin Ophthalmol.* 2010;4:1379-1382.†