

SCREENING AND TREATMENT OF RETINOPATHY OF PREMATURITY AT THE DEPARTMENT OF PEDIATRIC OPHTHALMOLOGY AT THE FACULTY OF MEDICINE, MASARYK UNIVERSITY AND UNIVERSITY HOSPITAL BRNO

Rozsypalová Marie, Autrata Rudolf, Šenková Kateřina

Department of Pediatric Ophthalmology Faculty of Medicine,
Masaryk University and University Hospital Brno, Czech Republic

The authors of the study declare that no conflict of interests exists in the compilation, theme and subsequent publication of this professional communication, and that it is not supported by any pharmaceuticals company. The study has not been submitted to any other journal or printed elsewhere, with the exception of congress abstracts and recommended procedures.

Submitted to the editorial board: April 9, 2024

Accepted for publication: June 4, 2024

Available on-line: August 27, 2024



MUDr. Marie Rozsypalová
Dětská oční klinika FN Brno a LF MU
Brno
Černopolská 9
61300 Brno
E-mail: rozsypalova.marie@fnbrno.cz

SUMMARY

Aim: Evaluation of screening and treatment of retinopathy of prematurity (ROP) at the Department of Pediatric Ophthalmology.

Material and Methods: Retrospective evaluation of the medical records of premature babies, born in the period 2012–2022 and treated at the Neonatology Department and the Neonatology ICU at the University Hospital Brno. On average 150 children annually are put forward for screening of ROP. A total of 1694 premature infants were examined during the 11-year monitored period.

Results: There were 100 patients who reached the stage of ROP requiring treatment, and the results showed that the most endangered group were those with a birth weight below 1000 g. The gestational age at the start of therapy was also assessed. Treatment of ROP was most often carried out by means of a combination of laser photocoagulation of the retina and intravitreal application of anti-VEGF (35 patients), as well as monotherapies: application of anti-VEGF (30 patients), laser photocoagulation of the retina (28 patients) and cryotherapy (2 patients in total). None of the patients reached ROP stage 4 or 5. The number of patients in need of treatment in the past three years has decreased significantly.

Conclusion: The article documents the screening and trend in the treatment of retinopathy of premature infants in recent years. Of interest here are the changes in the incidence of ROP from 2020, which reflect the positive development of neonatological care.

Retinopathy of prematurity is still a disease that can lead to blindness of premature infants, but early screening and treatment can prevent this. Progress in the care of newborns born prematurely is also positively reflected in the incidence of this serious disease.

Key words: retinopathy of prematurity, update of the international classification, screening, treatment

Čes. a slov. Oftal., 80, 2024, No. 6, p. 308–316

INTRODUCTION

Retinopathy of prematurity (ROP) was originally described as retrolental fibroplasia in the USA in the 1840s. Despite advances in the care of newborns, the condition still remains one of the leading causes of loss of sight in children worldwide.

ROP is the name for a vasoproliferative pathology of the retina that appears in prematurely born infants with incomplete development of the retinal blood vessels. The development of retinal vessels in the fetus begins in the 16th week of gestation from the optic nerve disc and progresses to the retinal periphery. It reaches the ora serrata nasally in the 36th week of gestation and temporally in the 40th week of gestation. Therefore, in prematu-

rely born infants the retina is not naturally fully vascularized, and depending on the gestational age a peripheral avascular zone may be present at birth [1].

ROP is the result of a multifactorial effect on the development of the vasculogenesis of the retina. These factors are linked with the development and progression of ROP, and include low gestational age, oxygen therapy, low birth weight, long duration of mechanical ventilation, noninvasive ventilation, administration of surfactant and late sepsis [2]. This pathology therefore requires a multidisciplinary approach, systematic screening, appropriate treatment and long-term monitoring.

In recent decades neonatal care has improved markedly, but despite this ROP remains the main cause threatening sight in children worldwide. The most important

aspect of the prognosis of ROP is prevention against progression to the severe stages, and a classification system of ROP has been created and revised in an endeavor to increase the effectiveness of this prevention [3].

IC ROP3

The new therapeutic procedures required the issuing of the third edition of the international classification of retinopathy of prematurity (IC ROP3) [4]. This concerns the use of anti-VEGF in the treatment of ROP, as well as innovated imaging techniques, also determining that the ROP findings in certain regions of the world do not fit precisely into the current classification system, and last of all an improvement in the objectivity of findings.

IC ROP3 retains current definitions such as the zone (location of pathology), stage (appearance of pathology on avascular-vascular connection) and the circumferential scope of the pathology.

The main update relates to:

1. New definitions of classification terms

Zone II is an annular region ranging nasally from the outer limit of zone I to the nasal ora serrata, and with a similar distance in the superior and inferior quadrants of the retina. The commission defined the region of a size of two diameters of the disc peripherally to zone I as posterior zone II in order to indicate potentially more alarming pathology than ROP in the more peripheral zone II.

The term “notch” was also introduced to describe the invasion of an ROP lesion with a length of 1 to 2 hours on the clock face along the horizontal meridian into the more posterior zone than the remainder of the retinopathy. If present, it should be recorded by the location of retinal vascularization, which is localized maximally posteriorly and termed “secondary to notch”. For example, ROP in zone II in most locations, but with a temporal notch encroaching into zone I should be termed “zone I secondary to notch”, thereby differentiating it from a finding in the eye in which the majority of the condition is present in zone I.

2. Definition of plus and pre-plus form of disease

Plus form of ROP defines the occurrence of dilation and tortuosity of the retinal vessels (Figure 1), whereas in pre-plus form there is abnormal dilation or tortuosity of vessels, which are not yet sufficient for a definition of plus form of the disease (Figure 2). These changes are evaluated according to the state of the vessels in zone I.

3. Stage of acute condition (stages 1–3)

The retina is not yet fully vascularized in prematurely born infants. If ROP is not present, it is recommended to use the term incomplete vascularization accompanied with a zone of vascularization (e.g. “incomplete vascularization into zone II”) rather than to use terms such as “without ROP” or immature retina (Figure 3). If acute vascular features of ROP develop on the interface of the vascularized and avascular retina, the term “stage” is used to describe the appearance. Stage 1 (demarcation line) (Figure 4), stage 2 (ridge) (Figure 5), stage 3 (extraretinal neovascular proliferation or flat neovascularization) (Figure 6). If more than one stage of ROP is present in the same eye, the eye is classified according to the most severe stage.

4. Aggressive ROP (A-ROP)

Aggressive – posterior ROP (Figure 1), as it was originally described, typically affects extremely prematurely born infants. Nonetheless, it has been observed with ever-increasing frequency that aggressive ROP is appearing also in larger prematurely born infants outside the posterior zone of the retina. Because the key diagnostic traits of this phenotype are the rate of progression of the disease and the incidence of vascular abnormalities, but not the localization of the condition, it is recommended to use the new term aggressive retinopathy of prematurity (A-ROP) instead of aggressive posterior ROP. A characteristic sign of A-ROP is the rapid development of pathological neovascularization and severe plus form of the disease, without progression being observed in the typical stages of ROP (Figure 7). In the initial stages of A-ROP, the retina may manifest capillary abnormalities posteriorly from

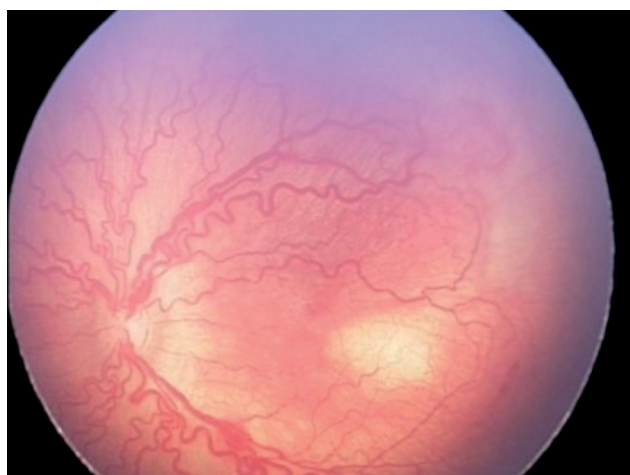

Figure 1. ROP plus disease
ROP – Retinopathy of Prematurity

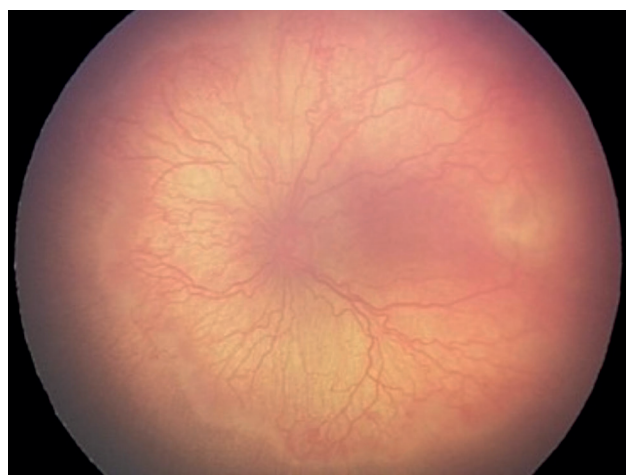


Figure 2. ROP preplus disease
ROP – Retinopathy of Prematurity

the original edge of the vascularized margin such as an A-V short-circuit resembling dilated vascular loops, and in certain extreme cases the loss of almost the entire vascularized retina may be evident. In posterior forms of the disease, in the initial stage the vessels in zone I may be thin. Eyes with A-ROP often manifest the stage 3 form of the condition, which may appear as seemingly indistinct networks of flat neovascularization which are difficult to image with the aid of a 28-D lens in ophthalmoscopy, but may be identified with the use of greater enlarging (e.g. 20-D lens) or fluorescence angiography. Extraretinal neovascularization has also been observed in eyes with A-ROP, as in the classic stage 3 of the condition.

5. Retinal detachment (stages 4 and 5)

- a) stage 4 is defined as partial retinal detachment:
 - stage 4A foveal region remains attached (Figure 8)
 - stage 4B foveal region is detached (Figure 9)
- b) stage 5 means complete retinal detachment, in which further subcategories are:
 - stage 5 A, in which the disc of the optic nerve is

ophthalmoscopically detectable (Figure 10)

- stage 5 B, in which the disc of the optic nerve is not ophthalmoscopically detectable as a consequence of retrolental fibrovascular tissue or retinal detachment of an occluded funnel type (Figure 11)
- in stage 5 C the previous stage is accompanied by changes on the anterior segment of the eye (e.g. shallowing of anterior chamber, iridocorneal-lenticular adhesions, corneal opacities)

6. Extent of pathology

The extent of the pathology is defined with the aid of 30° sectors or with the use of numbers of the clock face.

7. Regression

Until now the classification of ROP has focused on the acute condition, with less attention paid to regression. The introduction of anti-VEGF treatment presents new challenges. The clinical features and time frame of regression differs following anti-VEGF therapy and after laser

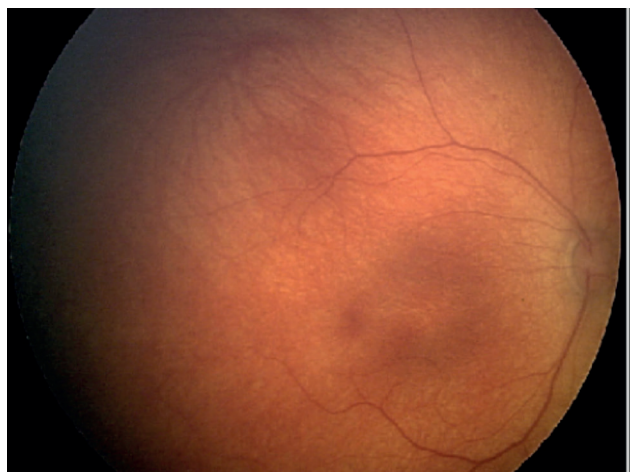


Figure 3. Incomplete retinal vascularization to zone II

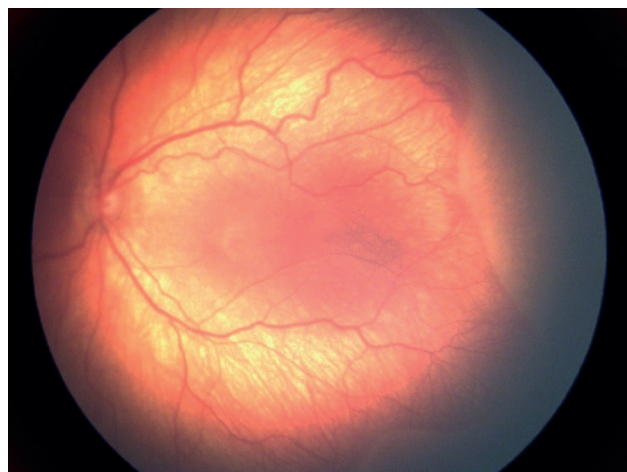


Figure 4. ROP stage 1, zone II
ROP – Retinopathy of Prematurity

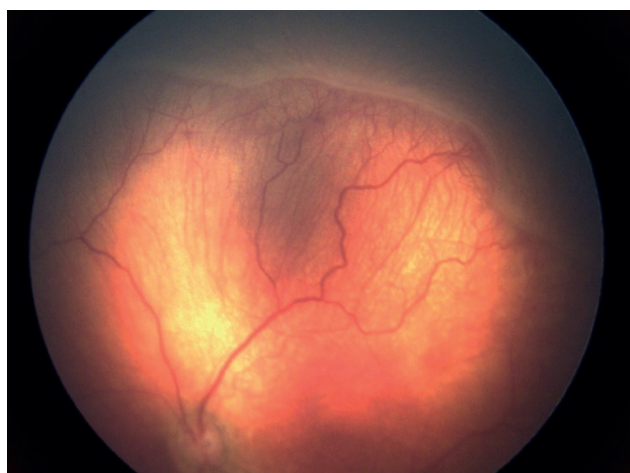


Figure 5. ROP stage 2, zone II, preplus disease
ROP – Retinopathy of Prematurity

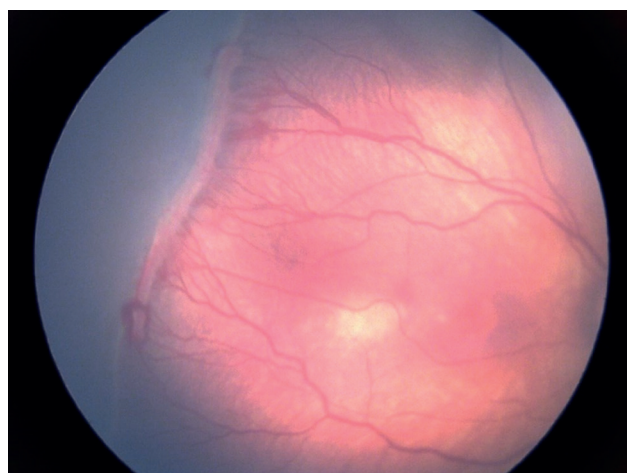


Figure 6. ROP stage 3, zone II
ROP – Retinopathy of Prematurity

treatment. It is recommended to use two terms:

1. Regression, in which a reduction and subsidence of signs of the pathology takes place, and
2. Reactivation, which relates to recurrence of features of the acute phase.

Regression may be complete or incomplete, including persistence of retinal abnormalities.

The first visible signs of regression are typically vascular, and have a tendency to manifest themselves more rapidly after anti-VEGF treatment (after 1–3 days) (Figure 12, 13) than after laser photocoagulation (approximately 7–14 days) (Figure 14–16) or during spontaneous regression. Other clinical symptoms of regression include involution of the tunica vasculosa lentis, better pupil dilation, greater transparency of optic media and subsidence of intraretinal hemorrhages.

Regression may be followed by complete or incomplete vascularization of the retinal periphery. Incomplete vascularization is referred to using the term persistent

avascular retina (PAR). After treatment with anti-VEGF agents, peripheral PAR occurs more frequently and should be documented by its position and scope.

8. Reactivation of ROP

Reactivation is observed more commonly following anti-VEGF treatment than after spontaneous regression. It rarely occurs following complete laser photocoagulation. Reactivation may occur following incomplete or complete regression of the original ROP lesion. Although the maximum interval until reactivation following injection with anti-VEGF agents is not yet known, current evidence indicates that it most commonly occurs between the 37th and 60th week of gestation. It may be influenced by the choice and dosing of the anti-VEGF agent.

Signs of reactivation range from the development of a new demarcation line to reactivated stage 3 with plus form of the condition. Reactivation need not take place

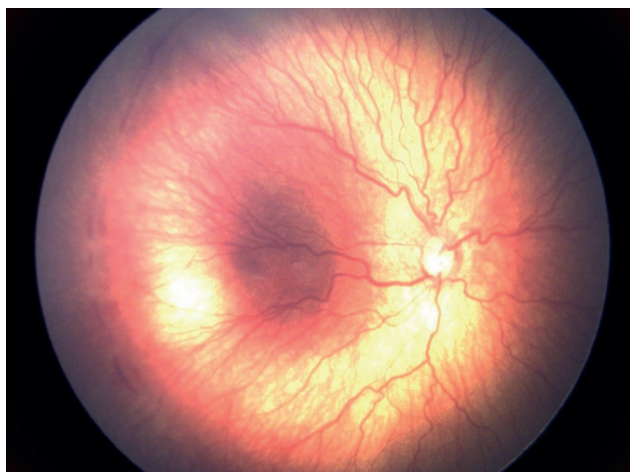


Figure 7. A-ROP
A-ROP – Aggressive Retinopathy of Prematurity

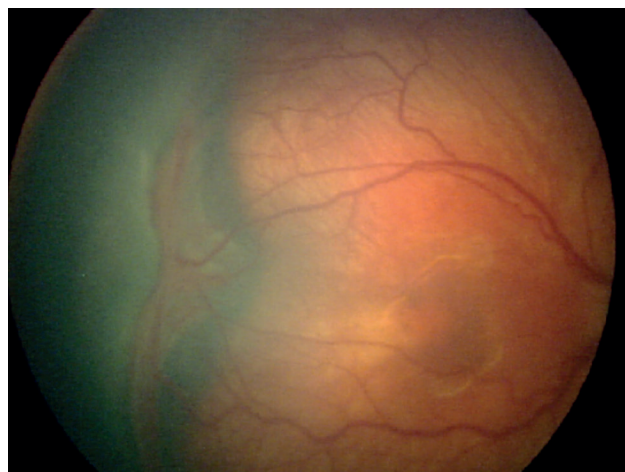


Figure 8. ROP stage 4 A
ROP – Retinopathy of Prematurity

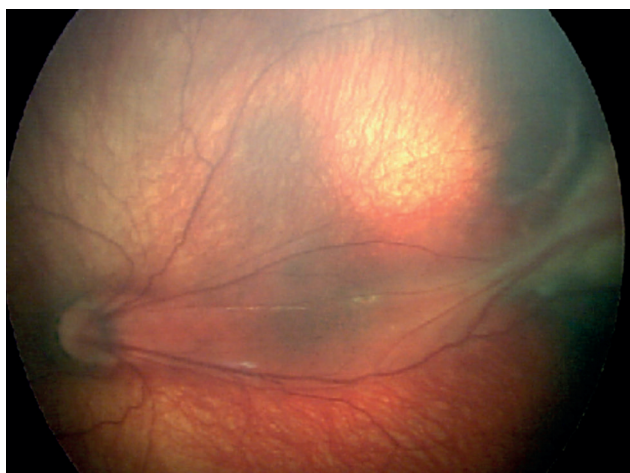


Figure 9. ROP stage 4 B
ROP – Retinopathy of Prematurity

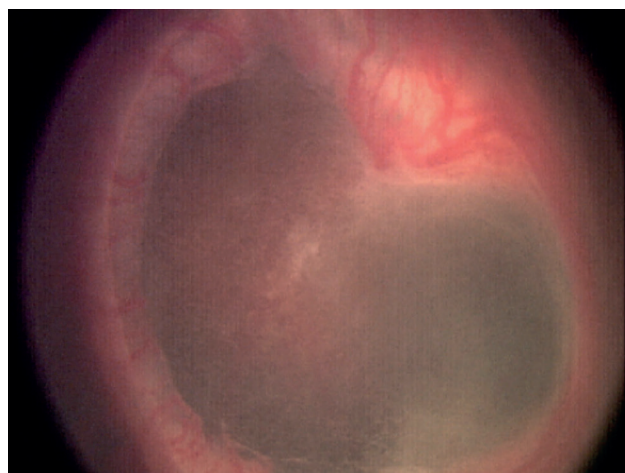

Figure 10. ROP stage 5 A
ROP – Retinopathy of Prematurity

through typical stages of the acute phase of the pathology (Figure 17).

9. Long-term consequences

Patients with a medical history of prematurity, even without an anamnesis of ROP, have a broad spectrum of ocular abnormalities, which may lead to permanent consequences. These incorporate late tractional, rhegmatogenous or (in rare cases) exudative retinal detachment, retinoschisis, persistent avascular retina with the risk of incidence of holes and lattice-like changes, macular anomalies, vascular changes and glaucoma.

MATERIAL AND METHOD

Screening of retinopathy of prematurity takes place once per week or once every two weeks according to the finding, until vascularization of the retina is complete. For

examination we use an indirect ophthalmoscope with a lens with a power of 20 D. It is essential for the patient to be in wide artificial mydriasis, and for an eye speculum to be used. Upon a finding of ROP which does not require treatment, follow-up examinations take place once per week until regression of the finding. Especial attention is paid to patients with severe form of ROP, in which the vessels end in zone I and in posterior zone II. In this case the patients are monitored more frequently, and are indicated for examination using a retinal camera with digital photo documentation. This examination is essential for assessing the scope of the finding, it enables detailed evaluation and assists in ensuring very good monitoring of the effect of treatment. The examination takes place under local anesthesia with the use of a speculum. A generally stabilized condition of the patient is a condition.

On average 150 patients are included for screening at our clinic. We examine infants born up to the 31st gestational

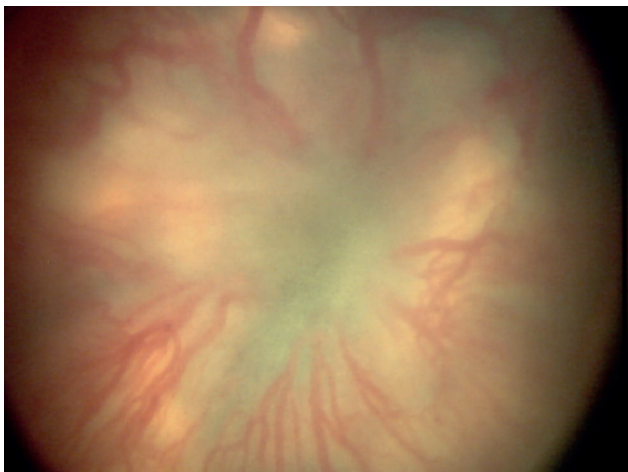


Figure 11. ROP stage 5 B
ROP – Retinopathy of Prematurity

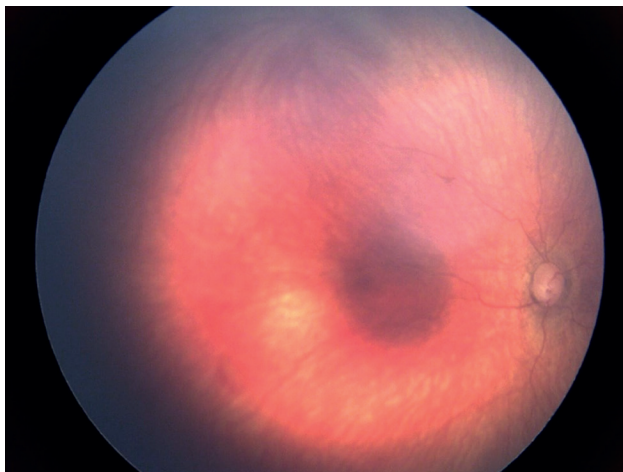


Figure 12. A – ROP – 3 days after anti – VEGF treatment (ranibizumab) in patient with A-ROP (finding before treatment in figure 7)
A-ROP – Aggressive Retinopathy of Prematurity

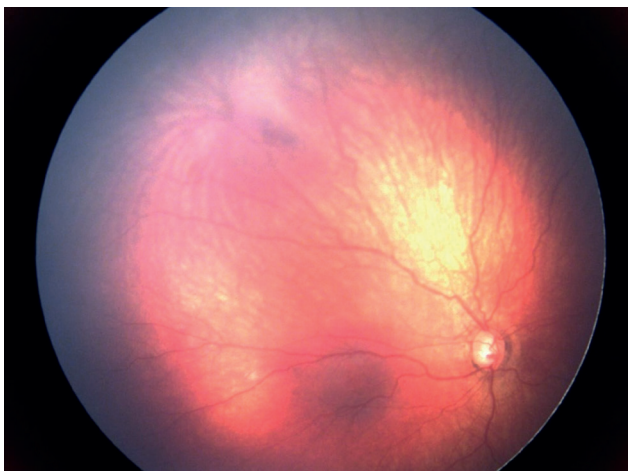

Figure 13. 4 weeks after anti – VEGF treatment (ranibizumab) in patient with A – ROP (finding before treatment in figure 7)
A-ROP – Aggressive Retinopathy of Prematurity

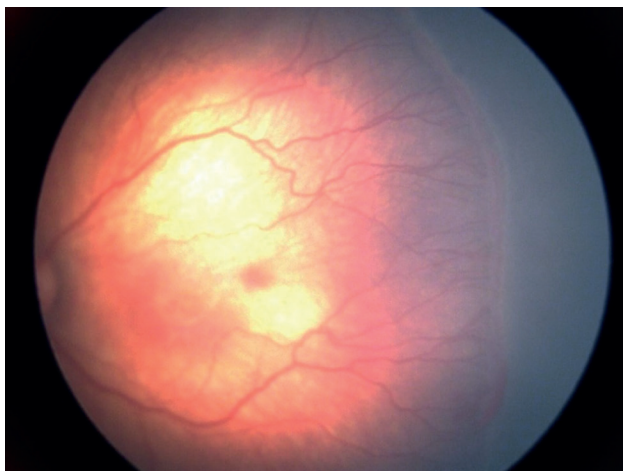


Figure 14. ROP stage 3, zone II, before laser photocoagulation
ROP – Retinopathy of Prematurity

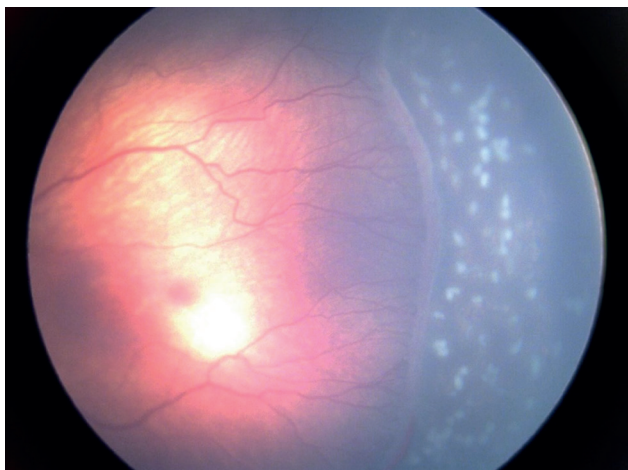


Figure 15. ROP stage 3, three days after laser photocoagulation
ROP – Retinopathy of Prematurity

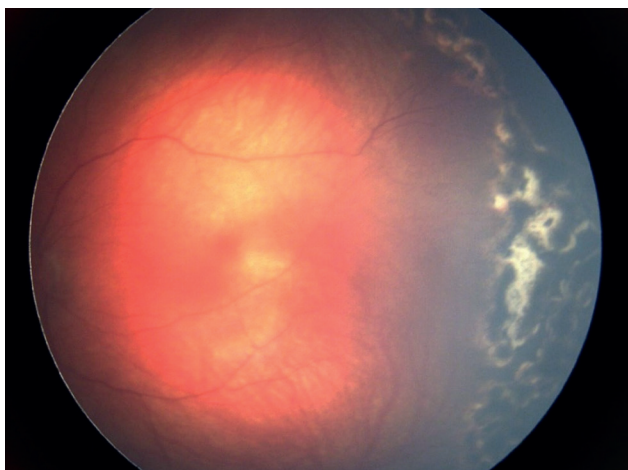


Figure 16. ROP stage 3, eight weeks after laser photocoagulation,
pigmentation of retinal deposits
ROP – Retinopathy of Prematurity

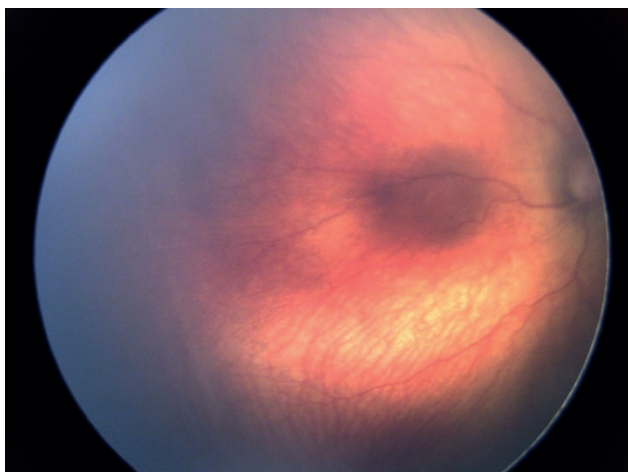


Figure 17. Beginning of reactivation 8 weeks after anti-VEGF treatment
– trace of line
ROP – Retinopathy of Prematurity

week (g.w.), i.e. 31+6 with a birth weight of less than 1501 g. If at least one of these criteria is met, screening is commenced in the 4th–7th week after birth. In some cases, prematurely born infants with a potential risk of occurrence of ROP such as respiratory distress syndrome (RDS), sepsis, blood transfusion, repeated oxygen therapy, apneic pauses, multiple births and intraventricular hemorrhage are also included in screening. Indication for screening is decided upon by a neonatologist together with an ophthalmologist [5].

RESULTS

Over the 11-year monitored period a total of 1694 infants were brought for screening at the Department of Pediatric Ophthalmology at the University Hospital Brno, of whom 100 infants required treatment of ROP. The screening in the individual years is illustrated in Table 1. In the last three years a decrease in the number of forms of ROP that required treatment has been observed at the Department of Neonatology at the University Hospital Brno. We can explain this by means of advances in neonatological care for prematurely born infants.

We divided all the treated children according to birth weight of under and over 1000 g. It is evident from Graph 1 that the group most at risk of the occurrence of ROP requiring treatment was that of infants with a birth weight of less than 1000 g.

Recommendation for treatment of ROP was reviewed on the basis of the clinical study on Early Treatment for Retinopathy of Prematurity, ETROP. Indication for therapy is pre-threshold ROP type 1, with high activity of the disease, in which prompt action is recommended. This incorporates all stages of ROP in zone 1 with plus form, as well as ROP 3 without plus form in zone 1 and ROP 2 or 3 with plus form in zone 2. The results of treatment improved after the introduction of this recommendation. However, this depends on the severity of the condition, and 30% of cases of high risk ROP in zone 1 have an unfavorable outcome in terms of vision [6].

Pre-threshold ROP type 2 incorporates ROP 1 or 2 in zone 1 without plus form and ROP 3 without plus form in zone 2, here this is followed only by monitoring until complete regression of the finding takes place, or conversely until progression to pre-threshold ROP type 1.

Therapy should be commenced within 48 to 72 hours from determination of the diagnosis [7].

In our cohort of patients, therapy was most often commenced in the 34th g.w. The distribution according to gestational age at the time of commencement of treatment is presented in Graph 2.

Therapy is based on reducing the level of VEGF in the eye. We achieve this either by reducing the surface of the avascular retina which produces VEGF, i.e. by thermocoagulation (photocoagulation/cryocoagulation), or by application of an anti-VEGF preparation intravitreally with unbinding of already produced vascular endothelial growth factor (VEGF) [8].

Developing retinal vessels grow from the optic nerve to the peripheral avascular retina [9]. The hypoxic environment is important because it stimulates VEGF, which

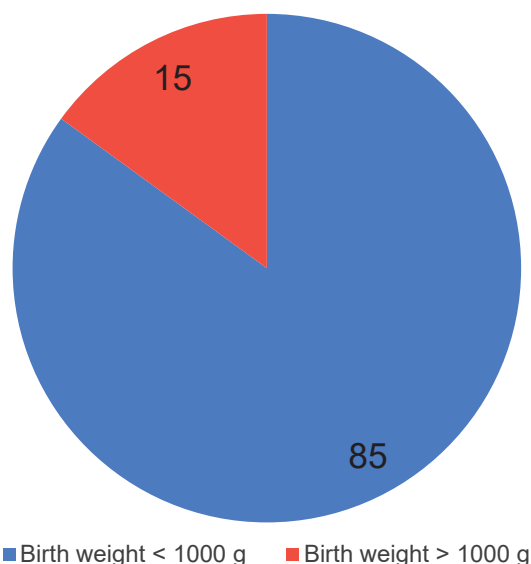
in turn stimulates growth of the retinal vessels to the periphery of the avascular retina. Low levels of oxygen in tissues increase regulation of VEGF, while hyperoxia reduces the level of VEGF. Prematurely born infants exposed to hyperoxia have reduced retinal VEGF, which halts the normal growth of vessels, resulting in an avascular retina. Long-term exposure to high levels of oxygen not only halts growth of vessels, but also leads to vasoconstriction and

ultimately to vaso-obliteration, because the vessels involute due to insufficient VEGF. Hyperoxia reduces the production of VEGF both in the retina and in the brain, which generates global vaso-obliteration of immature vessels, as can be seen in ROP and periventricular leukomalacia.

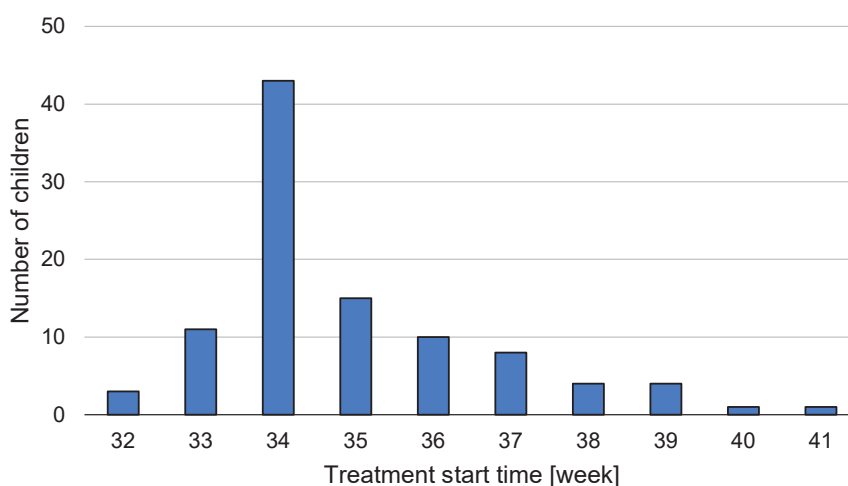
Over the course of time, usually within a matter of weeks, the avascular retina becomes ischemic, which stimulates late production of VEGF. In the region of the avascular retina is relatively small, physiological levels of VEGF are produced, stimulating normal growth of the retinal vessels. On the other hand, if the avascular region of the retina is large and a large quantity of VEGF is produced, this induces immature retinal vessels to sprout arterial venous (AV) shunts at the boundary between the vascularized and avascular retina (ROP stage 1–2).

Regression occurs if VEGF stimulates normal vascularization upon an AV shunt into the avascular retina. By contrast, extremely large regions of avascular retina increase the production of VEGF, stimulating neovascularization of the AV shunt (ROP stage 3). Persistently high levels of VEGF may even cause vasodilation and tortuosity of the existing vessels of the posterior pole (PLUS disease), dilation of the vessels of the iris and rubeosis of the iris.

Reduction of levels of retinal VEGF, either through photocoagulation of the peripheral avascular retina by means of applying laser treatment, or through the use of anti-VEGF preparations, leads to regression of neovascularization and reduces the risk of unfavorable development of the pathology. Extensive retinal neovascularization may cause retinal fibrovascular proliferation,



Graph 1. Distribution of patients in need of treatment based on birth weight



Graph 2. Distribution of patients based on age of a patients at the beginning of the treatment

Table 1. Summary of screening and treatment of ROP in years 2012–2022

Year	2012	2013	2014	2015	2016	2017	2018	2019	2020	2021	2022
Patients in total	145	144	140	133	140	130	139	112	130	125	126
Number of patients that underwent treatment	13	16	11	8	6	16	8	11	4	4	3
Percentage of patients that underwent treatment	9.0	11.1	7.9	6.0	4.3	12.3	5.8	9.8	3.1	3.2	2.4

ROP – Retinopathy of Prematurity

scarring and retinal detachment (ROP stage 4 and 5).

Laser photocoagulation (LFC) of the retina, intravitreal application of anti-VEGF, cryotherapy and a combination thereof was used on the observed cohort of patients. The most common form of treatment of retinas with ROP at our clinic was a combination of LFC and intravitreal application of anti-VEGF. We also treated patients in monotherapy consisting of LFC of the retina, application of anti-VEGF intravitreally, and less frequently the method of treatment was cryotherapy, which in recent years has been replaced by new therapeutic methods.

Cryotherapy was originally used for destruction of the retinal periphery by freezing the avascular retina via the outer scleral wall. Although it is effective, and in its time was revolutionary in comparison with modern techniques, the spectrum of side effects is broad [10]. During the course of our monitored period, cryotherapy was used a total of 2x as monotherapy for the treatment of ROP, and 3x a combined therapy followed by LFC and application of anti-VEGF intravitreally. In 2013 we performed the last cryotherapy in the treatment of ROP at our center.

Ablation of the avascular periphery by LFC diode laser is an effective treatment in the case of peripheral forms of ROP, which is illustrated also by the monitored 11-year period. The onset of regression of the condition is slower, and for this reason the time of this procedure is important. This is then followed by regular follow-up examinations of the retina.

Another option is the use of anti-VEGF agents intravitreally. In the monitored period from 2012 to 2020 we used bevacizumab in the treatment of ROP. Up to now we have not recorded any adverse effects attributable directly in connection with treatment using this preparation in the patients who remained monitored at our clinic. The patients were treated with bevacizumab in monotherapy, in the case of insufficient regression accompanied by LFC of the retina. Since 2020 we have been using ranibizumab for the treatment of ROP. This is the drug of first choice in the case of posterior findings of ROP and ROP of zone I. During the course of the 11-year moni-

tor period it was applied a total of 6x on patients with a diagnosis of ROP at our center, 3x in monotherapy and 3x supplemented by LFC of the retina (Table 2).

DISCUSSION

Effective treatment of ROP incorporates not only initial screening, but also frequent subsequent follow-up examinations. Timely detection and commencement of treatment of ROP is of crucial importance. The incidence of ROP is lower in countries with reliable screening and good neonatological care.

Studies have been published from several countries which state that both lower gestational age and lower birth weight are significant risk factors for the onset of ROP [11].

Discussion on individual types of treatment

Cryotherapy

Cryotherapy was the first ablation technique used in the treatment of ROP. However, it was associated with ocular complications, including periocular inflammation, ablation of extensive areas of the retinal periphery, retinal detachment, high myopia, traction and retinal puckering, with poor visual acuity [12,13].

Laser photocoagulation

For many years, the main treatment for ROP has been ablative indirect diode LFC of the avascular retinal periphery [10]. An advantage is the possibility of treating the entire band of the avascular retina on the interface of the vascularized and avascular part. However, it is not possible to perform the operation with a narrow, rigid pupil, upon filling of the vessels of the pupillary membrane, upon greater thickening of the avascular part of upon greater turbidity of the optic media. For this reason, it is not possible to wait so long with the indication as in the case of cryotherapy [8].

Anti-VEGF

In recent years treatment has turned in a direction away from destruction of the retina and inclined more towards the inhibition of angiogenic stimuli with the aid of anti-VEGF agents. In prematurely born infants it is necessary to consider the fact that anti-VEGF treatment could halt the normal vascularization of the retina [1]. This potential interference could then lead to later recurrences of neovascularization. In some cases, patients after anti-VEGF treatment require a longer period of monitoring as a consequence of retardation of normal vascularization.

Intravitreally applied drugs from the group of anti-VEGF agents have been used worldwide in the treatment of ROP: pegaptanib, bevacizumab, ranibizumab, aflibercept and conbercept [14,15]. Eyes with A -ROP and flat neovascularization are currently suitable primarily for treatment with anti-VEGF agents [16].

Bevacizumab has come into systemic circulation due to its longer systemic half-life in comparison with ranibizumab. Studies exist which have demonstrated a higher

Table 2. Summary of different types of treatment and number of patients

		Number of Patients		
		Once	No. of Repetitions	In total
Type of treatment	Cryo	2	0	2
	Laser ablation	26	2	28
	Anti-VEGF	26	4	30
	Laser ablation + Anti-VEGF	35	0	35
	Laser ablation + Cryo	0	0	0
	Laser ablation + Cryo + Anti-VEGF	3	0	3

Cryo – cryotherapy, Anti-VEGF – intravitreal anti-VEGF agents

risk of retardation of neurodevelopment in infants treated with anti-VEGF, but it is difficult to attribute this retardation to anti-VEGF therapy alone, because it is mostly the infants most at risk who receive the treatment. A definitive assessment of the risk of neurodevelopmental disorders would require further prospective studies [17]. The use of bevacizumab in ophthalmology is "off – label".

Ranibizumab was approved for use in ophthalmology by the State Institute for Drug Control in 2008. The effect of this preparation in the treatment of ROP was examined by a study which set itself the goal of systematically evaluating the clinical efficacy of intravitreal application of ranibizumab in the treatment of ROP.

A search was conducted of the databases MEDLINE (PubMed), Embase, China Biology Medicine disc, Cochrane Library, Web of Science, WanFang Data, CNKI and CQVIP with the aim of amassing randomized controlled clinical trials comparing the efficacy of ranibizumab with laser treatment in ROP [18]. It incorporated a total of five randomized controlled clinical trials comparing the efficacy of ranibizumab with laser treatment in ROP. The period of search was from 2007, when ranibizumab was approved, until January 12, 2022. In this study the degree of regression of neovascularization was used as the index

of therapeutic effectiveness. According to the results, the degree of regression of neovascularization of the retina in the group with intravitreal injection of ranibizumab was statistically higher than in the group with laser therapy, but the incidence of adverse effects, including recurrence and complications, did not differ between the two groups. The safety and efficacy of ranibizumab in the long-term treatment of ROP requires further investigation.

CONCLUSION

There have been substantial advances in recent years in the field of diagnosis, management and treatment of ROP. This mainly concerns neonatal care, anti-VEGF therapy, new imaging methods in ophthalmology with digitization of records and options in pediatric vitreoretinal surgery. The revised classification of ROP provides a basis for improvement of research and care of children with ROP in the future.

The areas on which further research is focusing on cover monitoring of vascular changes of the disease, characterization according to other imaging methods such as fluorescence angiography and OCT, understanding of the long-term risks of PAR (persistent avascular retina) and clarification of the signs of reactivation of ROP.

REFERENCES

1. Daruich A, Bremond-Gignac D, Behar-Cohen F, Kermorvant E. Rétinopathie du prématuré: de la prévention au traitement [Retinopathy of prematurity: from prevention to treatment]. *Med Sci (Paris)*. 2020 Oct;36(10):900-907. French. doi: 10.1051/medsci/2020163
2. de las Rivas Ramírez N, Luque Aranda G, Rius Díaz F, et al. Risk factors associated with Retinopathy of Prematurity development and progression. *Sci Rep*. 2020;12:21977.
3. Hong EH, Shin YU, Cho H. Retinopathy of prematurity: a review of epidemiology and current treatment strategies. *Clin Exp Pediatr*. 2022 Mar;65(3):115-126. doi: 10.3345/cep.2021.00773
4. Chiang MF, Quinn GE, Fielder AR, et al. International Classification of Retinopathy of Prematurity, Third Edition. *Ophthalmology*. 2021 Oct;128(10):e51-e68. doi: 10.1016/j.ophtha.2021.05.031
5. Wilkinson AR, Adams GGW, Fleck BW, Nieto-Hernandez R; Guideline Development Groups (GDG) of the Royal College of Paediatrics and Child Health (RCPCH) and the Royal College of Ophthalmologists (RCOphth). UK screening and treatment of retinopathy of prematurity Updated 2022 Guidelines. *Early Hum Dev*. 2023 Mar;177-178:105715. doi: 10.1016/j.earlhumdev.2023.105715
6. Kanski's Clinical Ophthalmology 2020; p.538.
7. Good WV; Early Treatment for Retinopathy of Prematurity Cooperative Group. Final results of the Early Treatment for Retinopathy of Prematurity (ETROP) randomized trial. *Trans Am Ophthalmol Soc*. 2004;102:233-248; discussion 248-520.
8. Zbořanová A, Brychcínová P, Autrata R, Šenková K. Screening, Treatment and Long-term Observation of Retinopathy of Prematurely Born Children in the Czech Republic. *Cesk Slov Oftalmol*. 2018;74(6):253-264.
9. Strube YNJ, Wright KW. Pathophysiology of retinopathy of prematurity. *Saudi J Ophthalmol*. 2022 Oct 14;36(3):239-242. doi: 10.4103/sjopt.sjopt_18_22
10. Wood EH, Chang EY, Beck K, et al. 80 Years of vision: preventing blindness from retinopathy of prematurity. *J Perinatol*. 2021 Jun;41(6):1216-1224. doi: 10.1038/s41372-021-01015-8
11. Yucel OE, Eraydin B, Niyaz L, Terzi O. Incidence and risk factors for retinopathy of prematurity in premature, extremely low birth weight and extremely low gestational age infants. *BMC Ophthalmol*. 2022 Sep 13;22(1):367. doi: 10.1186/s12886-022-02591-9
12. Dogra MR, Vinekar A. Role of Anti-Vascular Endothelial Growth Factor (Anti-VEGF) in the Treatment of Retinopathy of Prematurity: A Narrative Review in the Context of Middle-Income Countries. *Pediatric Health Med Ther*. 2023 Feb 15;14:59-69. doi: 10.2147/PHMT.S391591
13. Enríquez AB, Avery RL, Bauman CR. Update on Anti-Vascular Endothelial Growth Factor Safety for Retinopathy of Prematurity. *Asia Pac J Ophthalmol (Phila)*. 2020 Jul-Aug;9(4):358-368. doi: 10.1097/APO.0000000000000302
14. Sabri K, Ellis AL, Lee EY, Dutta S, Vinekar A. Retinopathy of Prematurity: A Global Perspective and Recent Developments. *Pediatrics*. 2022 Sep 1;150(3):e2021053924. doi: 10.1542/peds.2021-053924. PMID: 35948728
15. Autrata R, Krejčířová I, Šenková K, et al. Intravitreal pegaptanib combined with diode laser therapy for stage 3+ retinopathy of prematurity in zone I and posterior zone II. *E J Ophthalmol*. 2012 Sep-Oct;22(5):687-694. doi: 10.5301/ejo.5000166
16. Fierson WM; American academy of pediatrics section on ophthalmology; american academy of ophthalmology; american association for pediatric ophthalmology and strabismus; american association of certified orthoptists. Screening Examination of Premature Infants for Retinopathy of Prematurity. *Pediatrics*. 2018 Dec;142(6):e20183061. doi: 10.1542/peds.2018-3061. Erratum in: *Pediatrics*. 2019 Mar;143(3)
17. Hartnett ME. Retinopathy of Prematurity: Evolving Treatment With Anti-Vascular Endothelial Growth Factor. *Am J Ophthalmol*. 2020 Oct; 218:208-213. doi: 10.1016/j.ajo.2020.05.025, Erratum in: *Am J Ophthalmol*. 2021 Nov; 231:213
18. Wang Z, Zhang Z, Wang Y, Di Y. Effect of ranibizumab on retinopathy of prematurity: A meta-analysis. *Front Pharmacol*. 2022 Aug 22; 13:897869. doi: 10.3389/fphar.2022.897869