

Mitochondrial Retinopathy Due to MT-TL1 Mutation: The Role of Heteroplasmy. A Case Report

Arango Mauricio^{1,2}, Restrepo Sarita¹, Orrego Maria Antonia¹, Turizo Sara^{1,2}, Quintero-Lizcano Karol^{1,2}

¹Faculty of Medicine, Department of Ophthalmology, CES University, Medellín, Colombia

²Retina and Vitreous department, Clofán Clinic, Medellín, Colombia



First author:
Mauricio Arango, MD

Corresponding author:
Karol Quintero-Lizcano, MD
Cra. 48 No 19 A – 40, Clínica Clofán
Medellín
Colombia
E-mail: karolquinterolizcano@gmail.com

Submitted to the editorial board: November 26, 2024

Accepted for publication: January 3, 2025

Available on-line: February 13, 2025

The authors of the study declare that no conflict of interest exists in the compilation, theme and subsequent publication of this professional communication, and that it is not supported by any pharmaceutical company. The study has not been submitted to another journal and is not printed elsewhere, with the exception of congress summaries and recommended procedures.

SUMMARY

Objective: To report a case of mitochondrial retinopathy, highlighting its clinical and imaging findings, the importance of genetic confirmation, and the possible implications of heteroplasmy in this disease.

Material and Methods: Case report of a mitochondrial retinopathy secondary to m.3243A>G mutation in the MT-TL1 gene.

Results: A 32-year-old woman presented with bilateral vision loss, photophobia, and sensorineural hearing loss for more than 3 years. Best corrected visual acuity (BCVA) was 20/60 in the right eye (OD) and 20/25 in the left eye (OS). Fundus examination revealed multiple macular subretinal yellow-white deposits and central chorioretinal atrophy, without edema, hemorrhage, or subretinal fluid in the RE, and juxtafoveal atrophy with retinal pigment epithelium (RPE) metaplasia in the OS. Multimodal imaging raised suspicion of retinal dystrophy, and genetic testing confirmed a mitochondrial retinopathy secondary to the m.3243A>G mutation in the MT-TL1 gene.

Conclusions: Bilateral and symmetric RPE atrophic changes in young individuals, especially when associated with systemic symptoms, should prompt a comprehensive evaluation, including multimodal imaging and genetic testing. Identifying causative mutations and understanding the dynamics of mitochondrial DNA in the pathogenesis of these diseases is crucial for improving diagnosis and suggesting potential therapeutic strategies, including gene therapy.

Key words: mitochondrial disease, MT-TL1 gene, m.3243A>G mutation, heteroplasmy

Čes. a slov. Oftal., 81, 2025, No. 3, p. 159–162

INTRODUCTION

Mitochondrial diseases encompass a group of disorders that primarily impact organs with high energy demands, such as the brain, muscles, and retina. The retina is particularly susceptible to mitochondrial dysfunction due to its significant energy requirements. Impaired mitochondrial function can cause a spectrum of retinal changes, ranging from subtle alterations in the retinal pigment epithelium to widespread retinal atrophy, potentially compromising vision [1].

This case describes a 32-year-old patient with mitochondrial retinopathy caused by a mutation in the MT-TL1 gene. The variability in symptoms seen in these patients is largely influenced by a phenomenon known as heteroplasmy, which refers to the presence of both normal and mutated mitochondria within the same cell. This factor is crucial for the understanding of how mitochondrial dis-

eases manifest and progress in the retina, as illustrated by the case discussed.

CASE REPORT

A 32-year-old woman presented with a 3-year history of bilateral vision loss, photophobia, and sensorineural hearing loss. Her best corrected visual acuity (BCVA) was 20/60 in the right eye (OD) and 20/25 in the left eye (OS). The anterior segment examination was unremarkable. Fundus examination revealed multiple macular subretinal yellow-white deposits and central chorioretinal atrophy in the OD, without edema, hemorrhage, or subretinal fluid. In the OS, juxtafoveal atrophy with retinal pigment epithelium (RPE) metaplasia was noted. No peripheral retinal changes were observed in either eye (Figure 1).

Multimodal imaging was performed, including fundus autofluorescence (FA), which demonstrated a central area of diffuse granular hypoautofluorescence in both eyes associated with linear areas of hyperautofluorescence in the right eye (Figure 2). Optical coherence tomography (OCT) revealed RPE deposits corresponding to hyperreflectivity in the ellipsoid zone, with an increased distance between the ellipsoid and interdigitation zones in the OD. In the OS, external retinal atrophy was noted (Figure 3). All findings were confined to the posterior pole. These clinical and imaging features raised suspicion of retinal dystrophy.

Genetic testing confirmed the presence of the m.3243A>G mutation in the MT-TL1 gene, compatible with the diagnosis of mitochondrial retinopathy.

DISCUSSION

Mitochondrial diseases are commonly associated with systemic manifestations, which are influenced by different genetic phenomena. Heteroplasmy refers to the

coexistence of both normal and mutated mitochondrial DNA within a single cell and it explains phenotypical variability in these patients. In mitochondrial retinopathies, the RPE is particularly susceptible to mitochondrial dysfunction due to its critical role in photoreceptor metabolism and energy production [2,3]. As such, the degree of heteroplasmy in the retinal cells can significantly influence the severity and progression of retinal degeneration.

The m.3243A>G mutation in the MT-TL1 gene, a mutation in the mitochondrial tRNA gene encoding leucine, is associated with a variety of mitochondrial disorders. In this case, the mutation resulted in bilateral retinal degeneration, which is a hallmark of mitochondrial retinopathy [4]. The retinal changes observed in the patient, including macular subretinal deposits and RPE atrophy, are characteristic of mitochondrial involvement. However, the degree of heteroplasmy in the retina is a major determinant in clinical presentation and it can vary significantly between cells, tissues and individuals, even in cases with the same mutation [5]. In this patient, a presumable high mutation load in the retina likely explains the central vi-

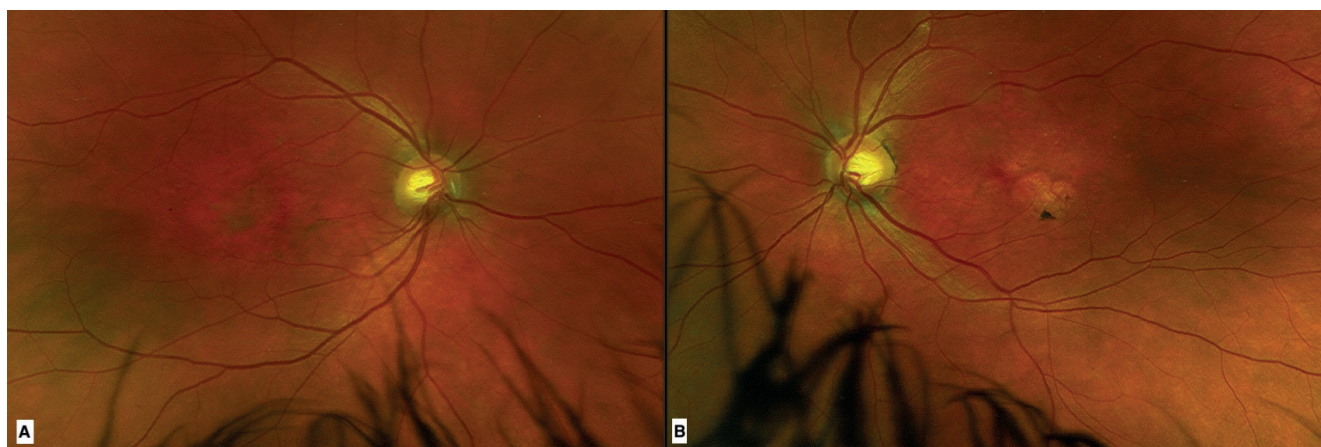

Figure 1. Color fundus photography with multiple subretinal yellow macular lesions in both eyes associated to central chorioretinal atrophy in the right eye (A) and juxtafoveal atrophy in the left eye (B)

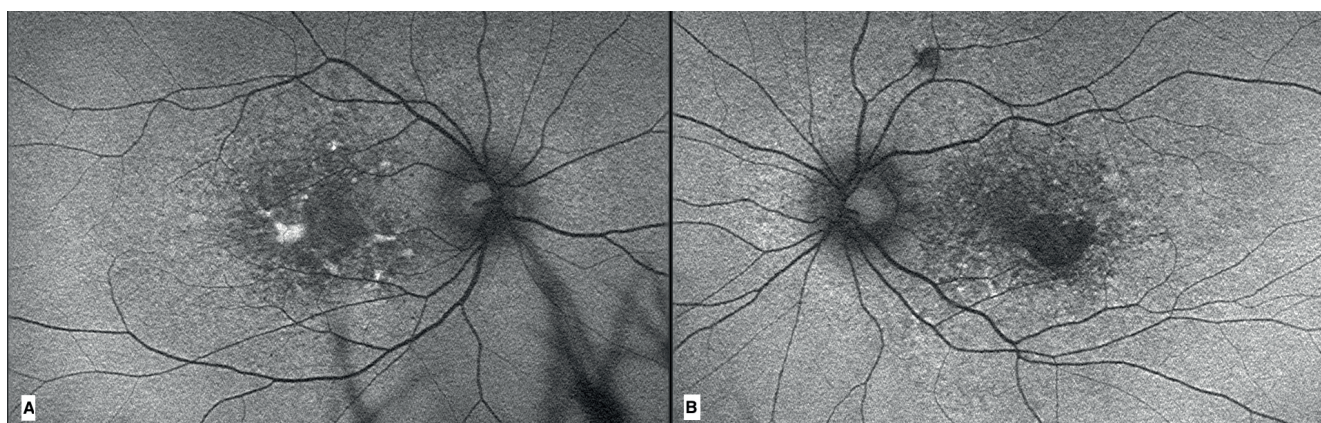


Figure 2. Fundus autofluorescence with diffuse macular granular hypoautofluorescence in both eyes with linear areas of hyperautofluorescence in the right eye (A) and a well-defined inferior parafoveal area of hypoautofluorescence in the left eye (B)

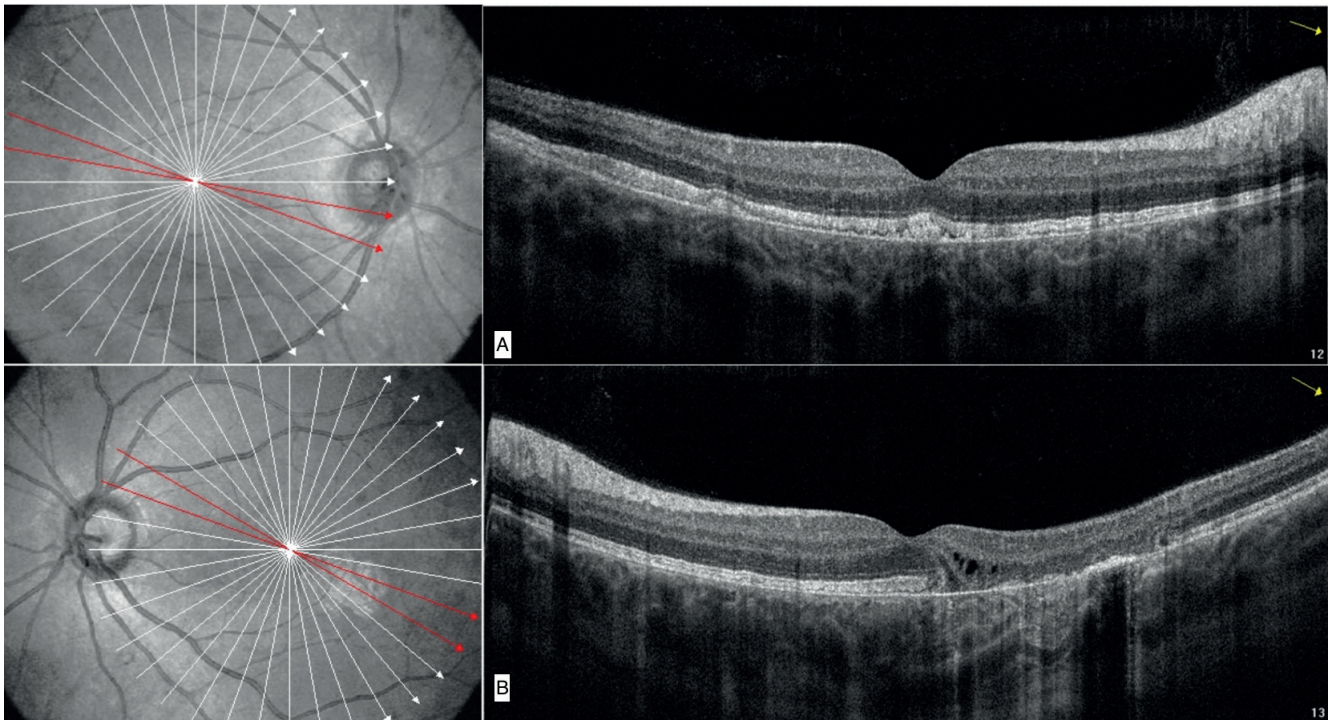


Figure 3. Optical coherence tomography revealed RPE deposits and ellipsoid hyperreflectivity in the right eye (A) and focal areas of RPE thickening, external retinal atrophy and hyporeflective intraretinal spaces in the left eye (B)

sion loss and retinal degeneration observed on OCT and fundus autofluorescence at a young age.

The retinal findings in this case were bilateral and partially symmetric, with similar patterns observed in both eyes, although some differences in severity and specific features were noted. This partial symmetry is characteristic of mitochondrial retinopathies. RPE atrophy is often progressive and can lead to significant vision loss. Interestingly, the fifth decade of life often marks a turning point for the onset of severe symptoms in individuals with mitochondrial mutations, although symptoms can appear earlier in life if there is a higher heteroplasmic mutant load in the affected tissues, as is the case here [6].

Multimodal imaging tools such as FA and OCT are invaluable in diagnosing mitochondrial retinopathies. These imaging modalities can detect subtle retinal changes, including RPE alterations, that may not be clinically apparent at initial presentation. In this case, OCT provided detailed information on the retinal layers, highlighting RPE deposits and external retinal atrophy, which are consistent with mitochondrial retinopathy. Furthermore, FA revealed characteristic hypo- and hyperautofluorescence patterns that correlate with the underlying retinal pathology.

Genetic confirmation of the m.3243A>G mutation in the MT-TL1 gene was crucial for diagnosing mitochondrial retinopathy in this patient. Since mitochondrial diseases are inherited maternally, the patient's family history is key in determining the risk of transmission to offspring. Genetic counseling is therefore an important aspect of managing such cases.

While gene therapy for mitochondrial diseases is still under investigation, identifying the specific mtDNA mutations in this patient holds promise for future therapeutic strategies. Targeted therapies, including mitochondrial replacement therapy and gene editing, could be developed to specifically address heteroplasmy and reduce the burden of mutated mitochondria in affected tissues. However, these approaches are still in the early stages of research, and mitochondrial retinopathy remains a challenging condition to treat.

CONCLUSIONS

This case emphasizes the critical role of heteroplasmy in the pathogenesis of mitochondrial retinopathy. The m.3243A>G mutation in the MT-TL1 gene is associated with a range of retinal findings, including bilateral macular deposits and RPE atrophy, which can result in progressive vision loss. Early diagnosis using multimodal imaging and genetic testing is essential for understanding the extent of mitochondrial involvement and for guiding management strategies. The recognition of heteroplasmy as a determinant of disease severity and progression is crucial for prognosis and personalized care. Furthermore, as advances in gene therapy and other mitochondrial-specific treatments continue, understanding the role of heteroplasmy will be pivotal in improving treatment outcomes for patients with mitochondrial retinopathy.

REFERENCES

1. Zeviani M, Carelli V. Mitochondrial Retinopathies. *Int J Mol Sci*. 2021 Dec 25;23(1):210. doi: 10.3390/ijms23010210
2. Birtel J, von Landenberg C, Gliem M, et. al. Mitochondrial Retinopathy. *Ophthalmol Retina*. 2022 Jan;6(1):65-79. doi: 10.1016/j.oret.2021.02.017
3. Li D, Liang C, Zhang T, et. al. Pathogenic mitochondrial DNA 3243A>G mutation: From genetics to phenotype. *Front Genet*. 2022 Oct 6;13:951185. doi: 10.3389/fgene.2022.951185
4. Kaisari E, Borruat FX. The spectrum of maculopathy in mitochondrial DNA A3243G mutation: A case series of six patients. *Klin Monats Augenhil*. 2021;238(4):414-417.
5. Chinnery PF, Hudson, G. Mitochondrial genetics. *Br Med Bull*. 2013;106(1):135-159. <https://doi.org/10.1093/bmb/lds062>
6. Nathaniel K. Mullin, Andrew P, et.al. Multimodal single-cell analysis of nonrandom heteroplasmy distribution in human retinal mitochondrial disease. *JCI Insight*. 2023 Jul;8(14):e165937. doi: 10.1172/jci.insight.165937