

THE EFFECT OF RETINAL TEAR LOCATION AND INTERNAL TAMPONADE ON THE SUCCESS OF PARS PLANA VITRECTOMY IN PATIENTS WITH UNCOMPLICATED RETINAL DETACHMENT

Straňák Zbyněk^{1,2*}, Veith Miroslav^{1,2*}, Dobaka Jan²,
Penčák Martin^{1,2}, Helman Karel³, Studený Pavel^{1,2}

¹Department of Ophthalmology, Faculty Hospital Královské Vinohrady, Prague, Czech Republic

²3rd Faculty of Medicine, Charles University in Prague, Czech Republic

³Faculty of Informatics and Statistics, University of Economics in Prague, Czech Republic

The authors of the study declare that no conflict of interests exists in the compilation, theme and subsequent publication of this professional communication, and that it is not supported by any pharmaceuticals company. The study has not been submitted to any other journal or printed elsewhere, with the exception of congress abstracts and recommended procedures.

Submitted to the editorial board: June 17, 2024

Accepted for publication: August 6, 2024

Available on-line: October 14, 2024



MUDr. Zbyněk Straňák, Ph.D.
Oftalmologická klinika Fakultní nemocnice Královské Vinohrady
a 3. lékařské fakulty Univerzity
Karlovy v Praze
Šrobárova 1150/50
100 34 Praha 10
E-mail: zbynek.stranak@fnkv.cz

SUMMARY

Aim: Retinal detachment is an acute sight-threatening condition that requires immediate surgical intervention. The aim of this study is to compare the outcomes of pars plana vitrectomy (PPV) for uncomplicated rhegmatogenous retinal detachment (RRD) between the different types of gases used, the position, and the number of tears.

Material and Methods: This is a retrospective non-randomized comparative study of patients with uncomplicated RRD treated at the Department of Ophthalmology from March 2018 to April 2021 using PPV. A total of 494 evaluated eyes were included in the study. The anatomical success of the surgery was monitored with regard to the extent of retinal detachment, the number and position of tears, and the tamponade used.

Results: The success rate of retinal reattachment with a single operation was 90.7% (448 eyes), and the final anatomical success rate was 100%. A very weak paired relationship was found between the success of the surgery for tears in the 4–8 hours region and the 9–3 hours region (89.1% vs. 92%). Similarly, no significant differences were observed between procedures using SF6 and C3F8 gases for RRD with a tear in the 4–8 hours region (success rate 93.4% for SF6 vs. 89.1% for C3F8). The average postoperative improvement of best corrected visual acuity was 29.6 ETDRS letters, and a gain of 15 letters was recorded in 55.1% (272 eyes). Overall, the complication rate was very low.

Conclusion: PPV is a safe and effective method for treating RRD. Extensive experience with this method allows the use of short-acting tamponades in selected patients.

Key words: pars plana vitrectomy, retinal detachment, gas tamponade

Čes. a slov. Oftal., 80, 2024, No. x, p.

INTRODUCTION

Rhegmatogenous retinal detachment (RRD) is an acute sight-threatening condition that usually requires surgical intervention without unnecessary delay. A number of surgical procedures are known for treating RRD, which include external approaches or e.g. pneumatic retinopexy, although pars plana vitrectomy (PPV) has become the method of choice at most centers due to its speed, safety and the relatively fast learning curve for inexperienced surgeons. Furthermore, the development of suture-free vitrectomy and advances in surgical techniques and equipment have made PPV very popular among surgeons [1,2]. Neverthe-

less, discussions are still ongoing regarding the optimal approach to PPV. Our aim was to evaluate the anatomical outcome with regard to the number and position of tears, the extent of detachment and the tamponade used.

MATERIAL AND METHOD

This is a retrospective non-randomized comparative study of consecutive cases operated on for RRD at the Department of Ophthalmology at Královské Vinohrady University Hospital in Prague. The cohort included all cases of RRD treated with 25- or 23-gauge PPV with gas or silicone oil tamponade, without the use of external

methods, in the period from March 2018 to April 2021. A total of 699 cases operated on by three experienced surgeons were included in the study. Of these, 152 eyes from our center or referential clinics were excluded before commencing the study due to previous unsuccessful PPV (72 cases from referential clinics and 80 cases from our center; note: one eye may have been operated on repeatedly). We further excluded 53 eyes with proliferative vitreoretinopathy (PVR) stage C or higher, patients with previous perforating ocular trauma and with an observation period of less than three months. The anatomical success of the surgery was monitored with regard to the extent of retinal detachment, the number and position of tears, and the tamponade used. On the other hand, our cohort included cases with a giant tear or patients with hypotonia or ablation of the choroid. A total of 494 eyes were evaluated, of which 194 were eyes of women and 300 were eyes of men. The mean age of the patients was 59.9 (median 59.3) years. In 194 cases the eyes were arthaphakic and in 299 cases phakic.

In our cohort we evaluated the anatomical success rate of surgery depending on the number and position of tears and the tamponade used. All the patients signed an informed consent form before undergoing surgery. The study protocol was governed by the principles of the Helsinki declaration.

The preoperative and postoperative evaluation incorporated examination on a slit lamp and biomicroscopic examination of the ocular fundus with the purpose of determining the extent of RRD, the localization and number of retinal tears, classification of preoperative PVR and also assessment of the postoperative condition of the retina. A fundamental observation parameter was the frequency of reattachment of the retina during a single operation.

Surgical technique

All the patients underwent three-port 25- or 23-gauge PPV. The instrument used was a Constellation® (Alcon, Fort Worth, TX, USA) with Ultravit® probe, with a cutting speed from 5000 to 7500 cuts/min. In all cases ports with flaps preventing perioperative turbulence of the fluid and hypotonia of the eyeball were used. A Leica PROVEO (Leica, Switzerland) microscope was used for visualization of the retina, with the wide-angle visualization system Biom (Oculus, Germany). After the performance of core vitrectomy and subsequent basectomy of the peripheral vitreous with assistance of scleral indentation by a light probe, depressor or finger, removal of the base of the vitreous around the retinal tears was performed, as well as removal of suspected lesions or retinal degenerations. This was followed by replacement with air in endodrainage of the subretinal fluid through the retinal tear with the aid of a Charles Flute (Alcon, Fort Worth, TX, USA) cannula or a vitrectomy probe without cutting. The retinal tears were usually treated by cryopexy, less frequently by endolaser, and the scope of treatment depended on the surgeon's de-

cision. In all cases the tamponade used was either 20% sulfur hexafluoride gas (SF6) (Alchimia, Italy), 15% octafluoropropane gas (C3F8) (Alchimia, Italy), or silicone oil (SO). The choice of tamponade was entirely within the competence of the surgeon, nevertheless at our center on a general level we prefer to use SF6 for patients with a retinal tear in the superior quadrants and C3F8 for patients with a tear in the inferior quadrants. We use SO relatively more often for patients undergoing surgery on the only seeing eye, in cases of multiple or giant tears primarily in the inferior quadrants, or upon the presence of higher stages of PVR. However, we also took further factors into account: presence and localization of other degenerations, ability of patients to position themselves after surgery, or condition of the other eye. At the end of the operation, we check ocular pressure and the tightness of sclerotomy. In the case of leakage of the tamponade we perform scleral massage or implement a Vicryl 8-0 suture (Ethicon, Johnson & Johnson Int), and subsequently supplement the tamponade.

Specific customs of center

In the case of phakic patients we do not usually remove the anterior vitreous membrane (due risk of damage to lens, thus retaining a barrier between the lens and the vitreous cavity). In the case of presence of vitreoretinal pathology (epiretinal membrane /ERM/, macular hole /MH/) we perform staining of these structures with the aid of brilliant blue (Ocublue, Aurolab, India), with subsequent peeling. We use perfluorodecalin (Arcaline, Arcadophta, France) relatively rarely, rather for stabilization of the posterior pole and to facilitate peripheral removal of the vitreous with a lower risk of iatrogenic retinal tear, but almost never in order to attain complete removal of the subretinal fluid, even in patients in whom certain surgeons were concerned about the formation of a retinal pucker in the macula. In cases where no retinal tear was found, retinotomy was performed with the aid of vitrectomy knife.

Statistics

With regard to its origin, our dataset cannot be considered a random sample from a clearly defined population, which led us to use tools of descriptive statistics. Analyses of paired comparison were used for an evaluation of the relationships between the variables within the analyzed dataset. In our analysis we therefore abide by the recent recommendations and heed calls to suppress any excessive role of statistical significance in scientific publications [3,4].

It is necessary to point out that the performed analysis does not enable "direct" causal conclusions, because the observed paired (statistical) relationships are not (and cannot be) purged of the influence of other factors which influence the relationship. In other words, the results of this analysis should not (cannot) be viewed as any kind of "evidence" concerning the existence (or nonexistence) of causal relationships. On the other hand, on the basis of the available dataset, the results presented in this article show detailed (paired) relation-

ships, which are the subject of interest. The entire analysis was performed within the RStudio program.

RESULTS

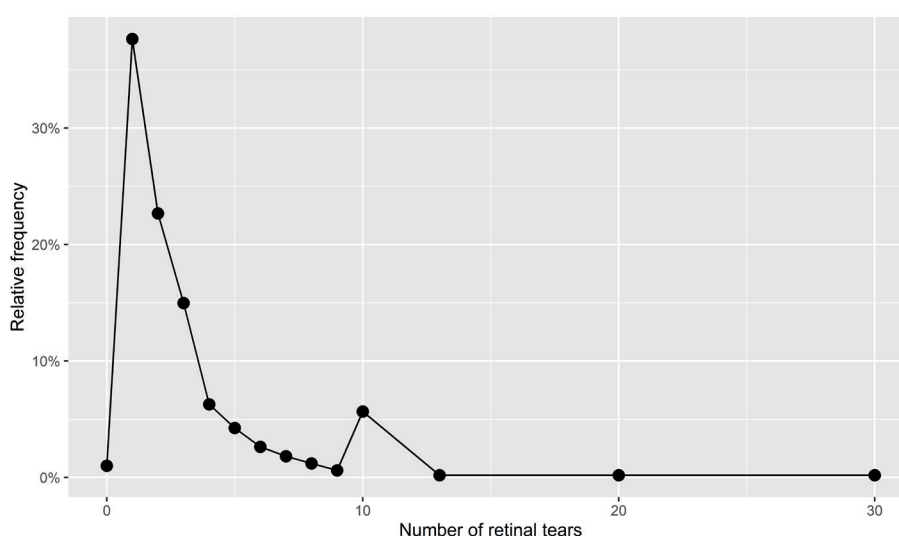
Fundamental parameters of cohort of cases

Within the context of retinal detachment, we most frequently recorded affliction of 2–3 quadrants (66.6%), total detachment was present in almost one quarter of eyes (22.5%), and only one quadrant was affected in 11% of the patients operated on. Most commonly one tear was present, as represented in Graph 1. “Number of tears 10” appears here relatively more often, which is caused by rounding up the number when filling out the operation protocol rather than a real anomaly of this number. Number of tears “0” represents a condition in

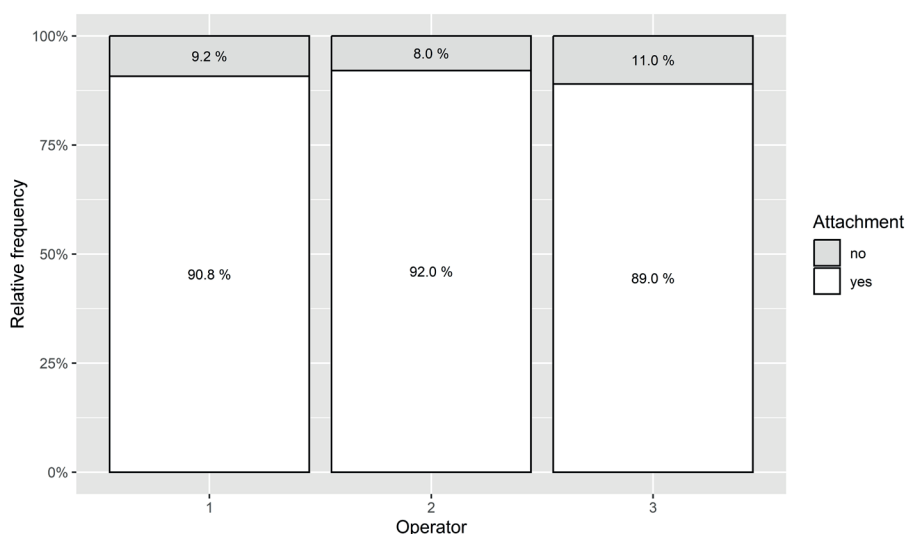
which we were unable to identify any tear.

Surgical technique

Our surgical technique has been described above [5]; here we present the relative frequency of the individual used modalities. The operations were performed by three experienced vitreoretinal surgeons. All three surgeons have a relatively comparable number of cases (173, 176 and 155) as well as results (Graph 2), in which there is only a weak paired relationship between the surgeon and the success rate of surgery within the analyzed cohort. In 94.5% ($n = 467$) of cases we used 25 gauge PPV, in 93.5% ($n = 462$) of cases we used cryopexy for treatment of the retinal tear, in 30.8% ($n = 152$) of cases we used laser photocoagulation (either for primary treatment of the tear or as adjuvant circular treatment



Graph 1. Frequency of retinal tears occurrences



Graph 2. Single surgery success rate by operator

(17.6%, n = 87) within the framework of prevention or in the case of suspected vitreoretinal lesions such as e.g. lattice degeneration), in 11.8% (n = 58) of cases we used decalin. We had to perform retinotomy in 10.3% (n = 51) of cases, and suture of sclerotomy in 12.9% (n = 58) of cases. In more than half of the operations we used SF6 as a tamponade (52%, n = 257), less often C3F8 (38.9%, n = 192) or SO (9.1%, n = 45).

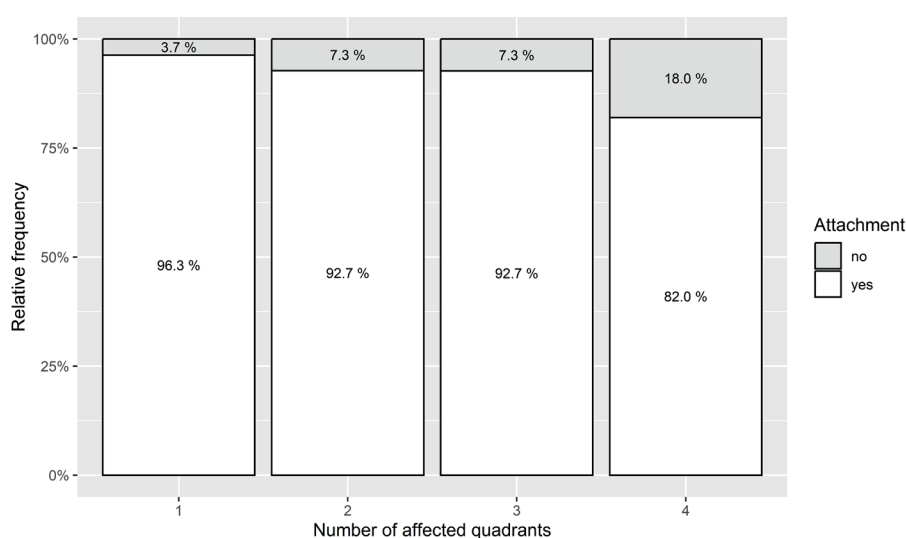
Visual acuity

A detailed analysis of changes of visual acuity is not the subject of this article, nevertheless the average gain of letters on ETDRS optotypes was 29.6 letters, in which this was naturally higher in the group with detached macula (42.1 letters) than in the group with a lying macula (10.8 letters).

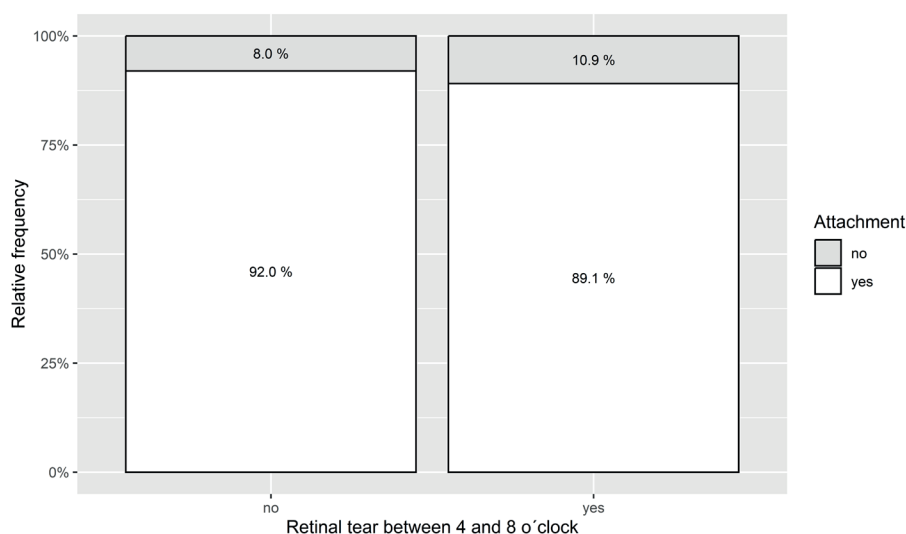
Morphological parameters

Graph 3 illustrates the correlation between the number of affected quadrants and the success rate of the operation. There is a medium-strong correlation here between the number of affected quadrants and the success rate. The greater the extent of retinal detachment, the lower the success rate of the operation – failure 3.7% (n = 18) in the case of affliction within the extent of one quadrant vs. 18% (n = 90) failure rate in total detachment.

The success rate of surgery according to localization of the tear is of interest. Here only a very weak relationship was demonstrated between localization of the tear and the success rate of the procedure – success rate 92% (n = 274) for tears in the superior quadrants vs. 89.1% (n = 220) for tears in the inferior quadrants, summarized in Graph 4.



Graph 3. Single surgery success rate Operation by number of affected quadrants



Graph 4. Single surgery success rate by location of retinal tears

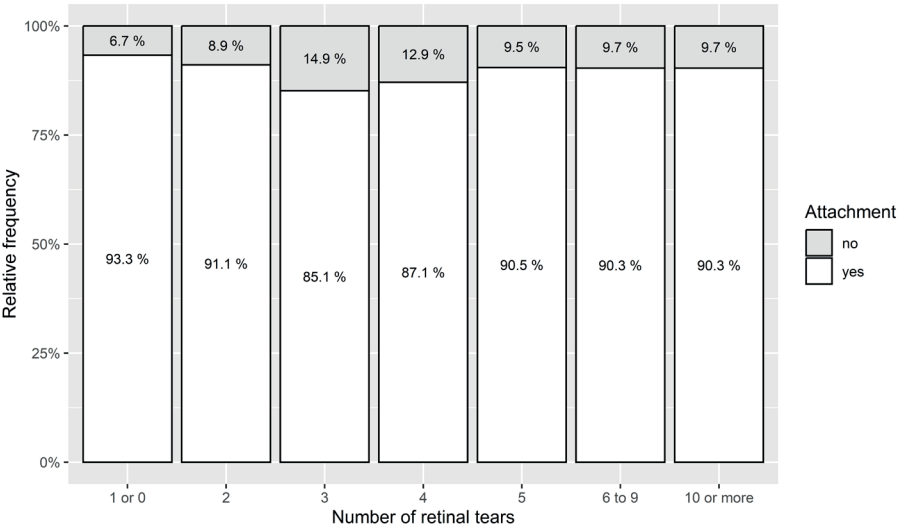
The last evaluated morphological factor was the number of identified tears. As is evident in Graph 5, here there is no relationship between the number of tears and the result of the operation. There is a relatively lower success rate in the region of 3–4 tears, nevertheless primarily in the group with three tears there are relatively fewer observations, and this may concern an error due to the small numbers.

Tamponade

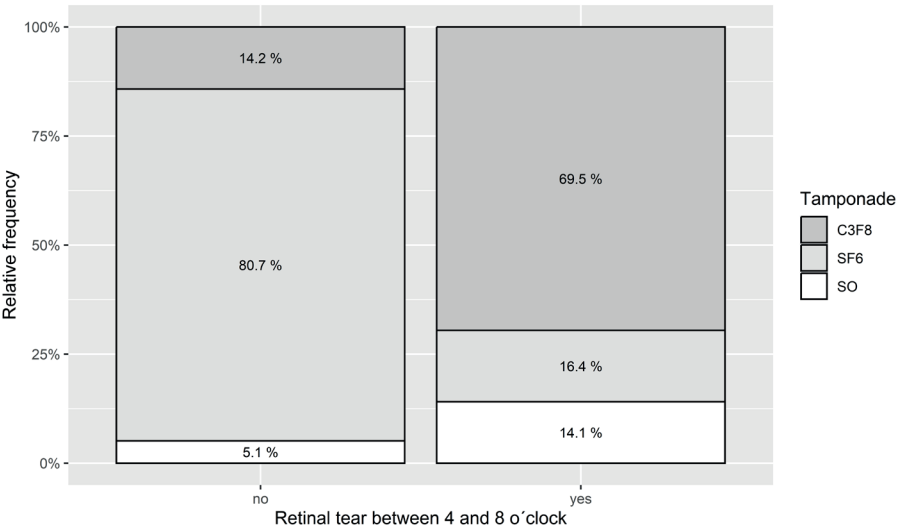
The final evaluated parameter was the influence of tamponade on the result of surgery. The frequency of use of individual types of tamponades is summarized in Graph 6, where we see a substantial shift from SF6 gas, which we choose more often in the case of “retinal detachment from above” due to its relatively quick absorption, to CF38 gas (or SO) in the case of “retinal detachment

from below”, where we tend to choose a longer-acting tamponade. In our cohort overall, the best results were achieved with SF6 gas, while by contrast worse results were produced in the case of tamponade with silicone oil.

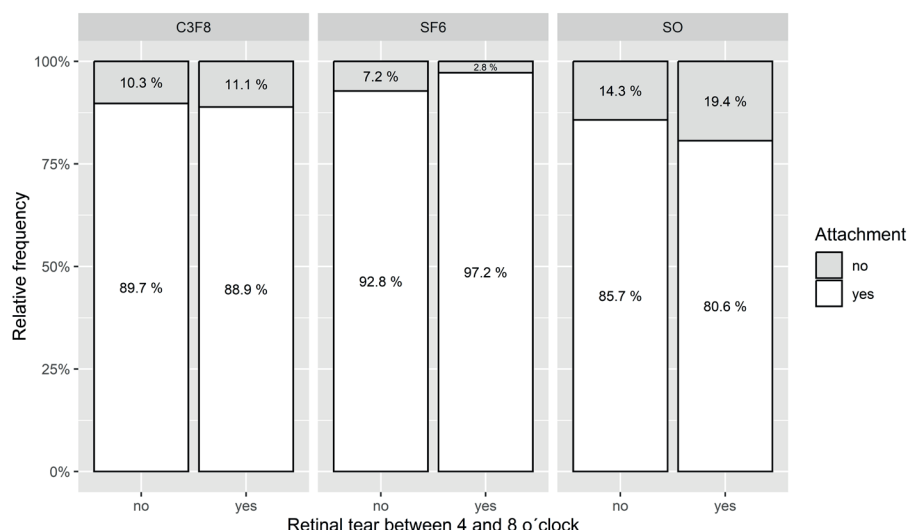
An interesting finding is offered by a comparison of the individual types of tamponade with regard to localization of the tear. No relationship exists within the analyzed dataset between the success rate of the operation and localization of retinal tear in the case of 15% C3F8 tamponade, and only a weak relationship in the case of SF6 20% tamponade or SO. In the case of use of SF6 the success rate of the operation is even slightly higher in the case of a retinal tear in the 4–8 hours region than in the case of a retinal tear in the 9–3 hours region. The characteristics of the analyzed dataset are thus at variance with the hypothesis that the use of 15% C3F8 is better in the case that a retinal tear



Graph 5. Single surgery success rate by number of retinal tears



Graph 6. Type of tamponade used by location of retinal tears



Graph 7. Single surgery success rate by location of retinal tears and type of tamponade

is located in the 4–8 hours region. The rate of successful operations with SF6 tamponade is 97.2%, compared with only 88.9% with C3F8 tamponade and 80.6% with SO tamponade. The data is summarized in Graph 7.

DISCUSSION

In our cohort we achieved successful reattachment of the retina within a single operation in 90.7% of patients, which is in accordance with the previous studies incorporated into the meta-analysis of the authors Eshtiaghi et al. [6], where the success rate of a single operation was on the level of 86.3%. At the end of the observed period, the anatomical success rate was 100%.

In 2022 Glovers et al. [7], as well as others [8,9], published a relatively extensive cohort of patients operated on for RRD exclusively with the aid of air tamponades, regardless of the extent or localization of the tear, with analogous results as in the case of SF6 or C3F8 gas tamponades. The data from the authors Glovers et al. are the result of operations performed by a single surgeon, who in cases of RRD first entirely desisted from the use of C3F8 (in 2018) and subsequently also SF6 (in 2020). The only significant difference from the technique we described was the performance of securing laser photocoagulation within the range of 360 degrees in each individual case at the conclusion of the operation. With regard to the use of tamponades our approach is more traditional, because we always use at minimum tamponade with fluorocarbon gas, and we never rely only on air. However, our results indicate that gas tamponade with SF6 could be an appropriate choice also for cases involving a retinal tear in the inferior parts of the retina. The higher success rate of SF6 in retinal detachment from below is nevertheless due among other factors to the absence of randomization, in which we evaluated the condition of the retina pe-

rioperatively and above all estimated whether patients would be able to properly position themselves.

It is universally accepted that firm adhesion of the retina and retinal pigment epithelium in the place of the tear is formed approximately 24 hours after the performance of the procedure, and the role of long-term tamponade is therefore contentious [10]. In contrast with this, we believe that positioning the patient face-down or on the opposite side from the tear after surgery could be an important factor in order to achieve successful results. However, thorough adherence to this position of the patient remains unclear [11]. Our approach also relies upon the effect of brief hospitalization, in which we have the security that patients are under the supervision of healthcare staff and emphasis is placed on rest and positioning. Furthermore, we exhort our patients to begin positioning themselves immediately after surgery, when still in the operating theatre. We thereby involve patients in the process of treatment and instill in them a sense of the importance of strict adherence to correct positioning as a critical component of the operation. In the case of macular detachment, the aforementioned Glovers et al. recommend positioning on the temporal side of the affected eye 45 minutes after surgery (in order to reduce the risk of retinal puckering), and subsequently according to the position of the tear. If the tear is in the superior quadrants, then positioning is not demanded.

Vingolo et al. [12] published the results of surgery in outpatient vs. hospitalized patients, in which 4.2% of eyes operated on in outpatient regime failed, in comparison with 1.5% of patients who were hospitalized for one night after surgery. Nevertheless, with the extension of hospitalization the incidence of repeat retinal detachment increased. This may be due to the retrospective character of the cohort, in which patients were discharged immediately after the first night in the case

of an uncomplicated procedure, whereas patients who were hospitalized for longer probably remained there due to some kind of complication.

A different perspective on this issue is presented by Zhou et al. [13]. The authors analyzed cases of repeat retinal detachment, in which the chief cause was a new or overlooked tear, which represented 48.9% of repeat detachments (this part of failed procedures could theoretically be eliminated by the use of the aforementioned 360-degree laser barrage, nevertheless we do not make use of this procedure at our clinic). Repeat opening of an original tear occurred in 43.8% of cases, and proliferative vitreoretinopathy was the cause of repeat detachment in 7.3% of cases. The median period until recurrence caused by repeat opening of an original retinal tear was 18 days, which supports the hypothesis that the adhesive power between the retina and RPE in the initial days after surgery may not be sufficient, and that a temporary restriction of physical activity could therefore be beneficial. The published data also reinforce the importance of careful perioperative evaluation of the retinal periphery; in our case we perform scleral indentation upon each operation, in which we investigate for further tears or tractions which we may have originally overlooked.

CONCLUSION

Pars plana vitrectomy is a reliable and reproducible method for the treatment of RRD. From the published data and according to the literature it appears that it is possible to use also shorter-acting gases, ideally air, without any increased risk for patients. This could be of great benefit to patients by shortening the time of their convalescence and reducing the risk of progression of cataract. In addition, due to the higher frequency of postoperative follow-up examinations shortly after the procedure, any repeat retinal detachment is diagnosed earlier. We also must not overlook the reduction of the risk of falling for older patients, which may be caused by the absence of spatial vision upon the use of long-term tamponades. Further auspicious benefits are the reduction of costs for surgery and the elimination of the use of highly potent greenhouse gases. For these reasons, and with reference to the results of this study, at our center we are partially transitioning to air tamponade for patients with retinal detachment.

REFERENCES

1. Hejsek L, Dusová J, Stěpanov A, Rozsival P. Operace rhegmatogenního odchlípení sítnice zevním postupem [Scleral buckling for Rhegmatogenous retinal detachment]. *Cesk Slov Oftalmol*. 2014;70(3):110-113. Czech.
2. Chrapek O, Šín M, Jirková B, Jarkovský J, Řehák J. Funkční výsledky kryochirurgických operací při rhegmatogenním odchlípení sítnice včetně makuly - naše zkušenosti [Functional Results of Cryosurgical Procedures in Rhegmatogenous Retinal Detachment Including Macula Region - Our Experience]. *Cesk Slov Oftalmol*. 2013;69(5):202-206. Czech.
3. Amrhein V, Greenland S, McShane B. Scientists rise up against statistical significance. *Nature*. 2019 Mar;567(7748):305-307. doi: 10.1038/d41586-019-00857-9
4. Mayo DG, Hand D. Statistical significance and its critics: practicing damaging science, or damaging scientific practice? *Synthese*. 2022;200(3):220. doi: 10.1007/s11229-022-03692-0
5. Veith M, Stranak Z, Pencak M, Vranova J, Studeny P. 25-Gauge Vitrectomy and Gas for the Management of Rhegmatogenous Retinal Detachment. *Acta Univ Palacki Olomuc Fac Med*. 2018;163(1):80-84.
6. Eshtiaghi A, Dhoot AS, Mihalache A, et al. Pars Plana Vitrectomy with and without Supplemental Scleral Buckle for the Repair of Rhegmatogenous Retinal Detachment: A Meta-analysis. *Ophthalmol Retina*. 2022 Oct;6(10):871-885. doi: 10.1016/j.oret.2022.02.009
7. Govers BM, Lamers MPM, Klevering BJ, Keijser S. Air versus fluorinated gas tamponades in pars plana vitrectomy treatment for primary rhegmatogenous retinal detachment. *Acta Ophthalmol*. 2022 Dec;100(8):e1600-e1605. doi: 10.1111/aos.15144
8. Nakamura M, Nishi K, Nishitsuka K. Selection Criteria for Air Tamponade During Vitrectomy for Rhegmatogenous Retinal Detachment. *Clin Ophthalmol*. 2022 Mar 30;16:981-986. doi: 10.2147/OPTH.S359936
9. Tan HS, Oberstein SY, Mura M, Bijl HM. Air versus gas tamponade in retinal detachment surgery. *Br J Ophthalmol*. 2013 Jan;97(1):80-82. doi: 10.1136/bjophthalmol-2012-302140
10. Li Y, Cheung N, Jia L, Zhang H, Liu N. Surgical outcomes of 25-gauge pars plana vitrectomy using air as internal tamponade for primary rhegmatogenous retinal detachment. *Retina*. 2020 Nov;40(11):2077-2082. doi: 10.1097/IAE.0000000000002744. PMID: 31922498
11. Liang Q, Sun D, Xue S, et al. A Comparison of Adjustable Positioning and Free Positioning After Pars Plana Vitrectomy for Rhegmatogenous Retinal Detachment: A Prospective Randomized Controlled Study. *Clin Ophthalmol*. 2023 Nov 6;17:3389-3396. doi: 10.2147/OPTH.S436825
12. Vingolo EM, Nebbioso M, Domanico D, Valente S, Frati P. Post-operative hospitalization in retinal detachment correlation to recurrences. *Ann Ist Super Sanita*. 2013;49(4):336-9. doi: 10.4415/ANN_13_04_03
13. Zhou C, Gu C, Li B, et al. The cause of redetachment after vitrectomy with air tamponade for a cohort of 1715 patients with retinal detachment: an analysis of retinal breaks reopening. *Eye Vis (Lond)*. 2023;10(1):9. doi:10.1186/s40662-022-00325-y