

Long-Term Refractive and Topographical Changes in Keratoconic Eyes after Accelerated Corneal Crosslinking

Benca Kapitánová Karolína^{1,2}, Javorka Michal³, Vida Rastislav¹, Ťazandlákova Monika¹, Budinská Miroslava¹, Králik Michal¹, Žiak Peter^{1,2}, Halička Juraj^{1,2}

¹UVEA Klinika s.r.o., Martin, Slovakia

²Ophthalmology Department, Jessenius Faculty of Medicine, University Hospital Martin, Slovakia

³Department of Physiology, Jessenius Faculty of Medicine, Martin, Slovakia

Submitted to the editorial board: June 3, 2024

Accepted for publication: July 30, 2024

Available on-line: August 25, 2024

The authors of the study declare that no conflict of interests exists in the compilation, theme and subsequent publication of this professional communication, and that it is not supported by any pharmaceuticals company. The study has not been submitted to any other journal.



MUDr. Karolína Benca Kapitánová,
PhD., FEBO

Correspondence address:

UVEA Klinika s.r.o.

Zelená 10888/1A

036 08 Martin

Slovensko

E-mail: kapitanova.k@gmail.com

SUMMARY

Aim: To evaluate the long-term impact of accelerated corneal cross-linking (A-CXL) on selected refractive and topographical parameters in eyes with progressive keratoconus.

Methods: 77 eyes with keratoconus in 54 patients treated with A-CXL (10 min "epi-off" protocol) were included in the analysis. Preoperative and postoperative (1, 3 and 5 years after A-CXL) values of the studied parameters were compared.

Results: In the cohort, there was an improvement in best corrected central visual acuity (BCCVA) 1 year ($p = 0.004$) and 3 years ($p < 0.001$) after A-CXL. Values of cylindrical component of refraction (D_{cyl}) ($p = 0.043$; $p = 0.009$; $p = 0.063$), maximum anterior corneal surface curvature (K_{max}) ($p = 0.003$; $p < 0.001$; $p < 0.001$), Coma aberration ($p = 0.023$; $p < 0.001$; $p = 0.005$) and minimum corneal thickness (Pachymin) ($p < 0.001$; $p = 0.003$; $p = 0.034$) were reduced at 1 year, 3 years and 5 years after surgery. The value of the steepest meridian of the anterior corneal surface (K_1) was reduced only at 3 years and 5 years after surgery ($p = 0.007$; $p = 0.012$). In the year-to-year comparison 1 year vs. 3 years after surgery, there was a continued improvement in K_1 ($p = 0.024$), the flattest meridian of the anterior corneal surface (K_2) ($p = 0.012$), K_{max} ($p = 0.001$) and Coma ($p < 0.001$) values, and this also applied 1 year vs. 5 years after A-CXL in the case of K_{max} ($p = 0.001$) and Coma ($p = 0.049$). We confirmed that the younger the patient at the time of A-CXL, the more pronounced the decline in K_{max} at the 3-year interval after the procedure. Furthermore, we observed a significant correlation between the maximum preoperative anterior corneal surface curvature (K_{max-0}) and the change in the D_{cyl} parameter 1 and 3 years after A-CXL, as well as between K_{max-0} and the postoperative decrease in K_{max} 5 years after surgery.

Conclusion: In the cohort, there was a favorable change in most of the analyzed parameters (BCCVA, D_{cyl} , K_1 , K_2 , K_{max} , Coma, and Pachymin) and a trend towards a further decrease in K_1 , K_2 , K_{max} and Coma values at 3 years, and subsequently in K_{max} and Coma at 5 years after surgery, was confirmed.

Key words: progressive keratoconus; accelerated corneal cross-linking; refractive and topographical parameters

Čes. a slov. Oftal., 81, 2025, No. 1, p. 8–13

INTRODUCTION

Keratoconus is a bilateral, progressive, clinically non-inflammatory corneal pathology, the precise etiopathogenesis of which has not been clarified to date [1]. It appears in adolescence to young adult age, and causes a progressive deterioration of uncorrected and corrected central visual acuity upon a background of corneal thinning, increased corneal curvature and the subsequent onset of irregular corneal astigmatism [2]. Corneal cross-linking (CXL) is a groundbreaking approach to the treatment that halts the progression of the disease by inducing cross-linking of the collagen fibres of the corneal stroma. This process is induced by a photochemical reaction occurring under the

influence of UV radiation in the riboflavin-soaked corneal stroma. The procedure was introduced by Wollensak et al. in 2003. Thanks to this procedure it is possible to halt the progression of the condition and thus avert the advanced state of the disease, when corneal transplantation is often the only option for improving severely deteriorated visual acuity in patients [3,4]. The standard (Dresden) protocol, following the impregnation of the corneal stroma with 20% riboflavin dextran solution, uses UV-A radiation with an intensity of 3 mW/cm² applied over 30 minutes, which leads to a total administered energy of 5.4 J/cm² [5]. With the aim of creating a more time-saving procedure, while retaining the effectiveness of standard CXL, protocols of accelerated corneal cross-linking (A-CXL) have been de-

veloped, modifying the intensity and duration of the radiation (Figure 1, 2). The most frequently used method today is the application of UV-A with an intensity of 9 mW/cm² over 10 minutes (5.4 J/cm²) [6]. Besides the crucial stabilizing effect on the cornea affected by keratoconus, topographical and refractive changes of the cornea have also been described following CXL and A-CXL, appearing especially in long-term postoperative period [7,8].

The aim of this study was to evaluate the long-term impact of A-CXL on selected refractive and topographical parameters in eyes with progressive keratoconus. Another aim was to determine the dependence between the age of the patients at the time of surgery as well as the selected initial values of the parameters ($K_{\max-0}$ – maximum preoperative anterior corneal surface curvature, $Pachy_{\min-0}$ – minimum preoperative corneal thickness), which are essential in determining the severity of the disease at the time of surgery and the effect of treatment expressed by changes in selected refractive and topographic parameters (spherical component of refraction – DSph, cylindrical component of refraction – DCyl and maximum curvature of the anterior surface of the cornea – K_{\max}) at the intervals of 1 year, 3 years and 5 years after surgery.

MATERIAL AND METHODS

In the period from October 2015 to August 2022, a total of 168 with progressive keratoconus (indication criteria according to the Global Delphi Panel of Keratoconus and Ectatic Disease, 2015) underwent treatment with A-CXL at the center UVEA Klinika s.r.o. in Martin, Slovakia [9]. After excluding the eyes of pediatric patients, eyes with a protocol of A-CXL without abrasion of the corneal epithelium and eyes after A-CXL with hypotonic riboflavin solution, 77 eyes of 54 patients (18 women and 36 men, age 25.0 ± 7.8 years) were included in the study and evaluated with the aid of a retrospective analysis.

The procedure was performed under local anesthesia (oxybuprocaine eye drops), in which initial abrasion of the

corneal epithelium within a scope of 9 mm with the use of 20% ethanol solution was followed by impregnation of the corneal stroma with 0.1% isotonic riboflavin solution with 20% dextran (MEDIOCROSS® D, Avedro Inc., USA) over 30 minutes. Subsequently UV-A radiation was applied with an intensity of 9 mW/cm² for a period of 10 minutes (LightLink CXLTM, Lightmed, USA). At the end of the procedure, local postoperative treatment was applied (levofloxacin/moxifloxacin eye drops and dexamethasone/fluorometholone eye drops) and a therapeutic contact lens was inserted. It was recommended to patients that they apply local postoperative treatment to the operated eye (levofloxacin/moxifloxacin eye drops and dexamethasone/fluorometholone eye drops, lubricants in the form of artificial tears without preservative agents). Initial postoperative follow-up checks were performed as standard 3-5 days after surgery, 3 months and 6 months after surgery, or in case of necessity at other individually set intervals. In the late postoperative period, we investigated the parameters (described below) in patients 1 year, 3 years, and 5 years after A-CXL.

The evaluated parameters in the observed cohort of eyes were as follows: uncorrected central visual acuity (CVA) in distance vision and best corrected central visual acuity (BCCVA) in distance vision examined on the optotype Topcon CC-100XP (Topcon Corporation, Japan), also spherical refraction component (DSph) according to measurement by the autorefractor keratometer Nidek ARK-1 (Nidek Co., Ltd., China), keratometric parameters of the anterior surface of the cornea (steepest meridian in central 3 mm zone – K_1 , flattest meridian in central 3 mm zone – K_2 , maximum curvature – K_{\max}), cylindrical refraction component (D_{cyl}), higher order aberrations (coma and spherical aberration) and minimum corneal thickness ($Pachy_{\min}$) of the cornea evaluated on the basis of corneal topography Schwind Sirius (Schwind eye-tech-solutions GmbH, Germany). Preoperative ($n = 77$) values were compared with postoperative values 1 year ($n = 74$), 3 years ($n = 52$) and 5 years ($n = 31$) after A-CXL. A statistical analysis was performed with the use of the statistical software SYSTAT (Systat

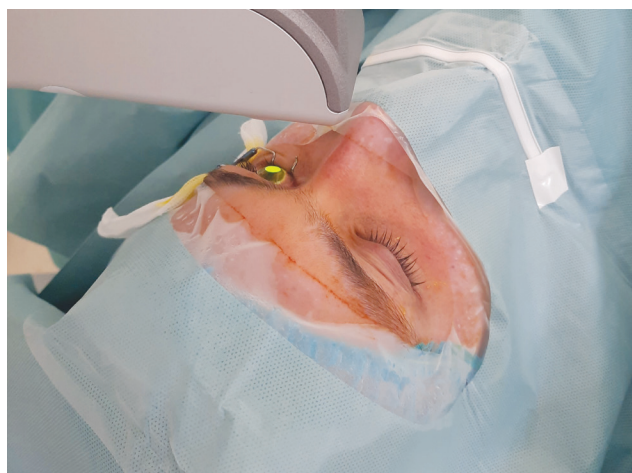

Figure 1. Accelerated corneal crosslinking. The course of application of UV-A radiation

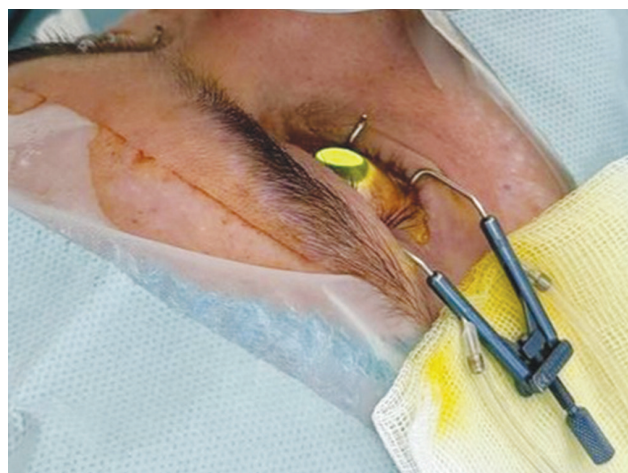


Figure 2. Accelerated corneal crosslinking. Detail of the UV-A radiation application process

Software Inc.) by applying a Wilcoxon test for comparison of the groups of preoperative and postoperative data, and a Spearman correlation coefficient for determining the statistical dependency between the analyzed parameters.

RESULTS

A summary of the preoperative and postoperative values of the analyzed parameters is presented in Table 1 and the results of the statistical comparison are shown in Table 2. In comparison with the preoperative values, a significant improvement of BCCVA was recorded in the cohort at 1 year ($p = 0.004$) and 3 years ($p < 0.001$) after A-CXL, but not at 5 years after A-CXL. The value of the cylindrical component of refraction (D_{cyl}) was significantly reduced compared to the preoperative value at 1 year, 3 years and 5 years after surgery ($p = 0.043$; $p = 0.009$; $p = 0.063$). There was no significant reduction of K_1 at 1 year ($p = 0.314$), but a significant reduction was recorded at 3 and 5 years after A-CXL ($p = 0.007$; $p = 0.012$). By contrast, in the case of K_2 we recorded a statistically significant reduction in the 3rd year of observation ($p < 0.001$) but not in the 5th year ($p = 0.766$). In the parameters Kmax, Coma and Pachymin we evaluated a statistically significant reduction at all three analyzed postoperative intervals (Table 2). In an inter-year comparison of 1 year vs. 3 years after surgery, the parameters K_1 ($p = 0.024$), K_2 ($p = 0.012$), K_{max} ($p = 0.001$) and Coma ($p < 0.001$) showed a continuing inter-year improvement (reduction). This trend was subsequently confirmed also in the parameters K_{max} ($p = 0.001$) and Coma ($p = 0.049$) also in the inter-year comparison of 1 year vs. 5 years after A-CXL.

An overview of the statistical dependency of the parameters of changes in D_{sph} , D_{cyl} and K_{max} from the preoperative value (parameters Δ) on maximum curvature of the anterior surface of the cornea (K_{max-0}) and minimum

corneal thickness (Pachymin₀), as well as on patient age at the time of surgery, analyzed 1, 3 and 5 years after surgery is presented in Table 3. We observed a significant positive correlation between the value of postoperative change in maximum anterior corneal curvature (K_{max}) and the age of the patients at the time of surgery, i.e., the younger the patient at the time of A-CXL, the more significant the decrease in K_{max} (more negative Δ value). However, this relationship was significant only for the interval 3 years after surgery. Furthermore, we observed a significant correlation between the baseline K_{max-0} value and the change in the D_{cyl} parameter, during both the 1- and 3-year postoperative periods. Also, a statistically significant correlation was confirmed between the K_{max-0} value and the postoperative decrease in the K_{max} value during the five years after surgery. Here, the higher the maximum curvature of the anterior corneal surface before surgery, the more its decrease occurs during the follow-up postoperative period. The numerical values for each eye for the selected significant correlations are shown in the scatter plots (Graph 1, 2, 3).

DISCUSSION

In contemporary ophthalmology, A-CXL is a method of treating keratoconus which makes it possible to halt the progression of the pathology, with effectiveness comparable to the standard Dresden protocol [10]. Changes in the anatomical and refractive properties of the cornea are also an important effect of A-CXL, which has been the subject of several studies and occupies an important place in the spectrum of results of this therapeutic procedure. In addition to this, its indirect impact on changes of the anatomical and refractive properties of the cornea is now well known, and this has been the subject of several studies and occupies an important place within the spectrum of results of

Table 1. Overview of preoperative and postoperative values of analysed parameters

	Baseline (n = 77)			1 st postoperative year (n = 74)			3 rd postoperative year (n = 52)			5 th postoperative year (n = 31)		
	AVG	SD	MED	AVG	SD	MED	AVG	SD	MED	AVG	SD	MED
UCDVA	0.39	0.27	0.3	0.39	0.27	0.4	0.43	0.27	0.4	0.48	0.27	0.6
BCDVA	0.74	0.22	0.8	0.8	0.2	0.8	0.83	0.2	0.9	0.78	0.23	0.9
D_{sph}	-2.04	2.45	-1.5	-1.77	2.56	-1.25	-1.75	2.86	-1.5	-0.5	2.49	0
D_{cyl}	-3.29	1.81	-3.32	-3.1	1.59	-3.0	-2.79	1.48	-2.66	-3.06	1.7	-2.76
K_1	48.75	3.82	47.86	48.37	3.42	48.01	48.01	3.46	47.39	46.93	3.67	46.9
K_2	45.38	2.95	44.75	44.9	2.69	44.72	44.7	2.8	43.98	43.84	2.86	43.76
K_{max}	55.38	4.44	55.22	54.88	4.54	55.01	54.74	4.47	55.0	53.57	3.99	53.79
Coma	1.92	0.93	1.91	1.89	0.91	1.79	1.77	0.75	1.74	1.76	0.95	1.84
SA	-0.01	0.5	0.12	0.02	0.43	0.09	0.11	0.43	0.19	0.11	0.37	0.13
Pachy _{min}	459	36	463	447	37	450	443	41	446	450	47	459

n – number of eyes analysed, AVG – average, SD – standard deviation, MED – median, UCDVA – uncorrected distance visual acuity, BCDVA – best corrected distance visual acuity, D_{sph} – spherical component of refraction, D_{cyl} – cylindrical component of refraction, K_1 – steepest meridian in central 3 mm zone of the anterior corneal surface, K_2 – flattest meridian in central 3 mm zone of the anterior corneal surface, K_{max} – maximum curvature of the anterior corneal surface, SA – spherical aberration, Pachymin – minimum corneal thickness

Table 2. Overview of the results of the comparison of preoperative and postoperative values of the analyzed parameters. Wilcoxon test, p-values. Significant values are highlighted in bold

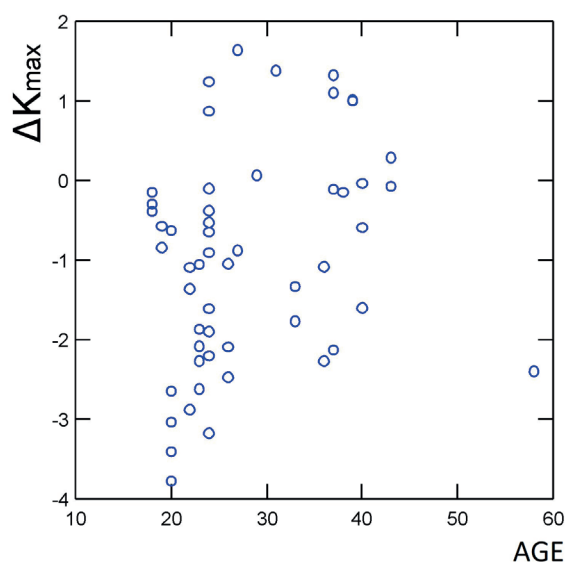
	Baseline vs. 1 year postoperatively	Baseline vs. 3 years postoperatively	Baseline vs. 5 years postoperatively
UCDVA	0.667	0.233	0.344
BCDVA	0.004 (increase)	<0.001 (increase)	0.312
D _{sph}	0.112	0.762	0.307
D _{cyl}	0.043 (decrease)	0.009 (decrease)	0.063 (decrease)
K ₁	0.314	0.007 (decrease)	0.012 (decrease)
K ₂	0.278	<0.001 (decrease)	0.766
K _{max}	0.003 (decrease)	<0.001 (decrease)	<0.001 (decrease)
Coma	0.023 (decrease)	<0.001 (decrease)	0.005 (decrease)
SA	0.876	0.143	0.992
Pachy _{min}	<0.001 (decrease)	0.003 (decrease)	0.034 (decrease)

UCDVA – uncorrected distance visual acuity, BCDVA – best corrected distance visual acuity, D_{sph} – spherical component of refraction, D_{cyl} – cylindrical component of refraction, K₁ – steepest meridian in central 3 mm zone of the anterior corneal surface, K₂ – flattest meridian in central 3 mm zone of the anterior corneal surface, K_{max} – maximum curvature of the anterior corneal surface, SA – spherical aberration, Pachy_{min} – minimum corneal thickness

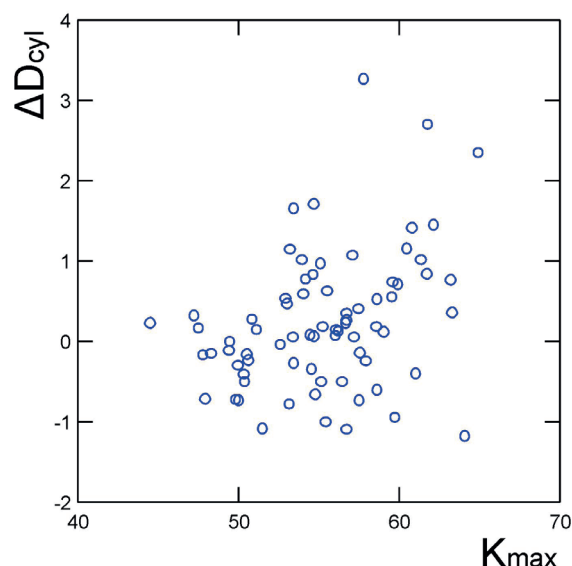
Table 3. Overview of the results of the evaluation of the statistical dependence between the analyzed parameters. Spearman's correlation test, p-values. Significant correlations are highlighted in bold, borderline correlations in italics

	ΔD_{sph}			ΔD_{cyl}			ΔK_{max}		
	1 st year (n=74)	3 rd year (n=53)	5 th year (n=31)	1 st year (n=74)	3 rd year (n=53)	5 th year (n=31)	1 st year (n=74)	3 rd year (n=53)	5 th year (n=31)
K _{max_0}	0.150	0.159	0.219	0.322	0.404	0.180	-0.122	-0.197	-0.435
Pachy _{min_0}	-0.206	-0.214	-0.206	-0.186	-0.149	0.149	0.015	0.059	-0.121
Age	-0.104	-0.082	-0.254	-0.064	-0.215	-0.150	0.146	0.344	-0.067

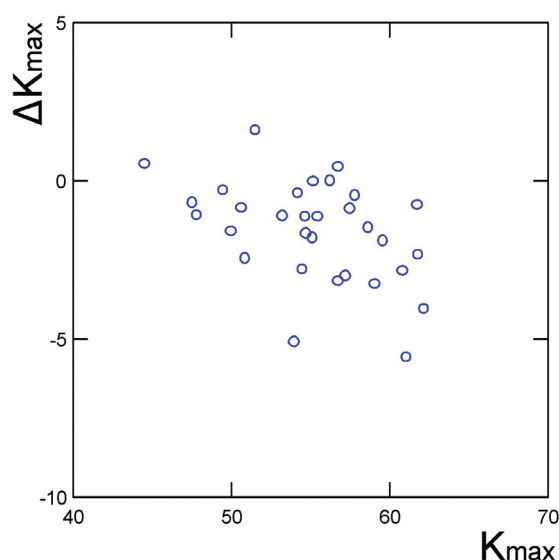
D_{sph} – spherical component of refraction, D_{cyl} – cylindrical component of refraction, K_{max_0} – maximum preoperative curvature of the anterior corneal surface, K_{max} – maximum curvature of the anterior corneal surface, Pachy_{min_0} – minimum corneal thickness



Graph 1. Scatter plot showing the change in maximum anterior corneal surface curvature (ΔK_{max} [D]) in individual eyes comparing the values at the time of the surgery with the values 3 years after A-CXL as a function of patients' age at the time of surgery



Graph 2. Scatter plot expressing the change in the cylindrical component of refraction (ΔD_{cyl} [D]) in individual eyes comparing the values at the time of the surgery with the values 1 year after A-CXL as a function of the maximum curvature of the anterior corneal surface at the time of surgery (K_{max} [D])



Graph 3. Scatter plot showing the change in maximum anterior corneal surface curvature (ΔK_{\max} [D]) in individual eyes comparing the values at the time of the surgery with the values 5 years after A-CXL as a function of the maximum anterior corneal surface curvature at the time of surgery (K_{\max} [D])

A-CXL. Although this is not the primary objective of the operation, knowledge of these consequences and the most precise possible quantification thereof are essential in order to enable us to estimate before the procedure the degree to which the refractive properties of the cornea may change due to the influence of A-CXL. This need becomes even more urgent in cases when we perform the procedure on an eye with preserved normal or almost normal CVA/BCCVA despite the confirmed progression of the pathology. According to a summary study from 2023 containing proposals for standard procedures in the management of keratoconus, waiting for a deterioration of visual acuity is not a condition for determining the progression of the pathology [11], and in a relatively extensive summary study from 2018 an algorithm for treatment by the CXL method is even proposed, in which an age of < 25 years is considered a criterion for immediate performance of CXL without the need to wait for confirmation of progression of the disease [12].

In our study we determined later postoperative changes in our cohort of eyes in several analyzed parameters, in which these changes were predominantly to a significant degree in the first, third and fifth year after surgery. An exception to this was the development of the value of K_1 , in which a significant reduction was recorded only in the third and subsequently in the fifth year after A-CXL, as well as in the case of the value of K_2 , in which a significant reduction was recorded only in the third year after A-CXL. In an inter-year comparison of 1 year vs. 3 years after surgery, a continuing improvement (reduction) was recorded in the values of the parameters K_1 , K_2 , K_{\max} and Coma, and this trend continued in the fifth year after surgery in the parameters K_{\max} and Coma. In contrast, we did not observe significant changes in CVA, Dsph and SA parameters after surgery.

In 2021 C. Mazzota et al. published a study analyzing the long-term influence of the same protocol of A-CXL as was evaluated in our cohort. In a cohort of 156 eyes with progressive keratoconus over a 5-year observation period they evaluated CVA, BCCVA, K_{\max} , D_{cyl} , Pachy_{\min} , Coma, and also the surface asymmetry index (SAI) of the cornea, endothelial cell density (ECD) and the position of the demarcation line according to anterior segment optical coherence tomography. From the third month after surgery, they recorded a significant improvement of both CVA and BCCVA, which persisted until the end of the 5-year observation period. From the sixth month after surgery to the end of the fifth year there was a significant reduction in K_{\max} , and from the first month after surgery until the end of the fifth year a significant improvement of Coma. By contrast with our results, after a significant reduction in the initial postoperative month, at six months after A-CXL the value of Pachy_{\min} returned to its preoperative level and remained there until the end of the 5-year observation period. In contrast with our conclusions, the change of D_{cyl} was not evaluated as significant in their cohort [6].

M. de Bernardo et al. evaluated a cohort of 57 eyes with progressive keratoconus, in which they compared the finding before standard protocol CXL and 24 months after surgery. As in our cohort, they too recorded a significant improvement of BCCVA and a significant reduction in the values of Pachy_{\min} and K_{\max} at an interval of 2 years after surgery. In addition, by contrast with our study they also evaluated changes of parametric data (axial length – AL, corneal volume – CV, anterior chamber depth – ACD, anterior chamber volume – ACV), corneal hysteresis – CH and corneal resistance factor – CRF. Of these, they recorded a significant change 24 months after surgery in their cohort only in the parameters CV and AL, although the study also included eyes of pediatric patients [13].

In a study by P. Veselý et al. on a cohort of 29 eyes, similarly as in our study the authors observed a significant improvement of D_{cyl} and Pachy_{\min} . They also evaluated Coma, CVA and BCCVA, although they did not record any statistically significant change. However, in comparison with our 5-year period the observation interval was relatively short, specifically 12 months after A-CXL performed by the same protocol as in our cohort of eyes. In addition, they also evaluated further topographical parameters – steepest, flattest and mean anterior instantaneous curvature (AICS, AICF, AICM) and posterior instantaneous curvature (PICS, PICF, PICM), the Cone Localization and Magnitude Index- CLMlaa and corneal thickness in the center (PACHC) [14].

Long-term changes in 34 eyes with progressive keratoconus were analyzed 10 years after standard protocol CXL by the authors F. Raiskup et al., who congruently with the results of our own study also determined a statistically significant improvement of BCCVA, K_1 , K_2 and K_{\max} . In addition, they also observed endothelial cell density, which did not change 10 years after CXL. In contrast with our study, the evaluated cohort of eyes also included pediatric

ric patients (mean age 28.4 ± 7.3 years, age range from 14 to 42 years), and in 13 eyes (38.2%) the authors stated the occurrence of a persistent decrease of transparency – haze in the anterior stroma [15].

M. Eslami et al. observed a relatively large cohort of 150 eyes at an interval of 3, 5 and 7 years after standard CXL. Similarly, as in our cohort, in this study too a statistically significant improvement was confirmed in the parameters BCCVA, D_{cyl} , K_{max} and Coma. In addition, the authors also observed a decrease in the values of average keratometry (K_{mean}), and in contrast with our results also a reduction of SA ($p = 0.003$) and D_{sph} ($p < 0.001$), in which the values furthermore continued to decrease in an inter-year comparison. However, they did not record a significant decrease of spherical equivalent in the cohort [8].

CONCLUSION

In the evaluated cohort of patients after A-CXL we recorded a demonstrably significant improvement in most of the analyzed refractive and topographic parameters. Furthermore, in long-term observation a trend of continuing improvement was demonstrated in some values over the three to five years following surgery. Compared to previously published papers dealing with the topic of refractive and topographic corneal changes after A-CXL, our work additionally demonstrated a relationship between the age of the patients and the maximum curvature of the anterior corneal surface at the time of surgery and a decrease in selected refractive and topographic parameters in the late postoperative period.

REFERENCES

1. Vazirani J, Basu S. Keratoconus: current perspectives. *Clin ophthalmol*. 2013;7:2019-2030.
2. Rabinowitz YS. Keratoconus. *Surv Ophthalmol*. 1998;42:297-319.
3. Wollensak G, Spoerl E, Seiler T. Riboflavin/ ultraviolet-A-induced collagen crosslinking for the treatment of keratoconus. *Am J Ophthalmol*. 2003;135:620-627.
4. Caporossi A, Mazzotta C, Baiocchi S, Caporossi T. Long-term results of riboflavin ultraviolet a corneal collagen cross-linking for keratoconus in Italy: the Siena eye cross study. *Am J Ophthalmol*. 2010;149(4):585-593.
5. Raiskup F, Spoerl E. Corneal crosslinking with riboflavin and ultraviolet A. I. Principles. *Ocul Surf*. 2013;11(2):65-74.
6. Mazzotta C, Raiskup F, Hafezi F, Torres-Netto EA, Armia Balamoun A, Giannaccare G, Bagaglia SA. Long term results of accelerated 9mW corneal crosslinking for early progressive keratoconus: the Siena Eye-Cross Study 2. *Eye Vis (Lond)*. 2021 May 1;8(1):16.
7. Salman A, Ali A, Rafea S, et al. Long-term visual, anterior and posterior corneal changes after crosslinking for progressive keratoconus. *Eur J Ophthalmol*. 2022 Jan;32(1):50-58.
8. Eslami M, Ghaseminejad F, Dubord PJ, Yeung SN, Iovieno A. Delayed topographical and refractive changes following corneal cross-linking for keratoconus. *J Clin Med*. 2022 Mar 31;11(7):1950.
9. Gomes JAP, Tan D, Rapuan ChJ, et al. Global Consensus on Keratoconus and Ectatic Diseases. *Cornea*. 2015 Apr;34(4):359-369.
10. Kandel H, Abbondanza M, Gupta A, Mills R, Watson AS, Petsoglou C, Kerdraon Y, Watson SL. Comparison of standard versus accelerated corneal collagen cross-linking for keratoconus: 5-year outcomes from the Save Sight Keratoconus Registry. *Eye (Lond)*. 2024 Jan;38(1):95-102.
11. Deshmukh R, Ong ZZ, Rampat R, et al. Management of keratoconus: an updated review. *Front. Med*. 2023 Jun;10:1212314.
12. Mohammadpour M, Heidari Z, Hashemi H. Updates on Management for Keratoconus. *J Curr Ophthalmol*. 2017 Dec 6;30(2):110-124.
13. De Bernardo M, Capasso L, Lanza M, et al. Long-term results of corneal collagen crosslinking for progressive keratoconus. *J. Optom*. 2015;8:180-186.
14. Veselý P, Veselý Ľ, Combová V, Žukovič M. Specific corneal parameters and visual acuity changes after corneal crosslinking treatment for progressive keratoconus. *Cesk Slov Oftalmol*. 2021;77(4):184-189.
15. Raiskup F, Theuring A, Pillunat LE, Spoerl E. Corneal collagen cross-linking with riboflavin and ultraviolet-A light in progressive keratoconus: Ten-year results. *J Cataract Ref Surg*. 2015;41:41-46.