

Vessel Density and the Retinal Nerve Fiber Layer in Pathological Intraocular Pressure

Jakub Král, Ján Lešták, Martin Fůs

Faculty of Biomedical Engineering Czech Technical University in Prague;
Kladno, Czech Republic



First author:
Mgr. Jakub Král

Corresponding author:
doc. MUDr. Ján Lešták
Katedra přírodovědných oborů
Fakulta biomedicínského inženýrství ČVUT
v Praze
nám. Sítná 3105
272 01 Kladno 2
Česká republika
E-mail: lestak@seznam.cz

Submitted to the editorial board: November 5, 2024

Accepted for publication: January 18, 2025

Available on-line: February 13, 2025

The authors of the study declare that no conflict of interests exists in the compilation, theme and subsequent publication of this professional communication, and that it is not supported by any pharmaceuticals company. The study has not been submitted to any other journal or printed elsewhere.

SUMMARY

Aim: The aim of the study was to determine the correlation between intraocular pressure (IOP) and thickness of the retinal nerve fiber layer (RNFL), and vascular density (VD) in the optic nerve.

Material and methodology: IOP was greater than 21 mmHg (21–36 mmHg) in all eyes and was measured as the result of an average of three measurements with the instrument Ocular Response Analyzer (ORA, Reichert). RNFL and VD thickness (in the papillary region of 4.5 x 4.5 mm) was measured with the instrument Avanti RTVue XR (Optovue). In the case of the VD, the scan area was further separated into individual anatomical segments. In the case of corrected RNFL (RNFLc), the VD value was subtracted from the total RNFL value. The relationship of IOP to VD, RNFL and RNFLc in each peripapillary segment was determined using a Pearson's correlation coefficient.

Results: The most significant correlation with IOP was observed for small vessel VD in a full scan ($r = -0.48$) and VD in the IT segment ($r = -0.48$). A similar correlation was observed for IOP and RNFL ($r = -0.42$). No statistically significant correlation was observed for RNFLc.

Conclusion: We demonstrated that VD values, specifically WI-VDs and peripapillary VDs in the IT segment, are significant markers for the early diagnosis of glaucoma.

Key words: vessel density, retinal nerve fiber layer, intraocular pressure

Čes. a slov. Oftal., 81, 2025, No. 4, p. 182–186

INTRODUCTION

Glaucoma is a progressive disease, in which a fundamental role for the preservation of visual functions is played by timely diagnosis and commencement of treatment. With reference to its asymptomatic nature, the timely detection of the disease before its severe stages is demanding, and the number of patients diagnosed with glaucoma is smaller than the number of undiagnosed patients [1,2]. For example, in China the diagnosis rate of primary open-angle glaucoma is only 10% [3].

The algorithm of damage to the individual retinal structures and the optic nerve is of substantial significance for the timely diagnosis of glaucoma. With the use of mouse models, Soto et al. determined that degeneration of the retinal ganglion cells (RGCs) in glaucoma has two separate stages: the first encompasses atrophy of the ganglion cells and the second damage to their

axons. Retrolaminar degeneration of the axons takes place before the degeneration of their intraretinal part [4]. With reference to these findings, we were interested in the experimental study conducted by Tao et al., who following a prior increase in intraocular pressure (IOP) in mice determined vascular remodeling of the retina; the number of capillary branches was reduced in the superficial and intermedial vascular plexus. The number of RGCs, the diameter of the central retinal arteriole and the deep branching of the capillary plexus were not influenced. These previously unappreciated findings indicate that a transitional increase in IOP may cause an undetected and potentially long-term pathology of the RGCs and the connected neovascular units [5]. Similar findings were determined also by Pitale et al., who following a temporary increase in IOP for a period of 2 weeks in a similar experiment on mice determined a normal number of RGCs, but a significant reduction in

the number of capillary connections/mm² in the inter-medial retinal capillary plexus, which spared the other plexuses. The density of the capillary connection, the length of the vessels and the vascular surface were significantly reduced, and the number of acellular capillaries dramatically increased [6].

In a previous study, we also demonstrated a medium correlation between vascular density (VD), the retinal nerve fiber layer (RNFL) and IOP in eyes in which IOP was higher than 20 mmHg [7]. Because the VD value also has a significant share in the overall value of the RNFL, we performed “cleaning” of the RNFL from VD (RNFLc) in individual peripapillary segments. The result was the finding that an increase in IOP plays a more significant role in VD than in the corrected RNFL [8–10]. This is important information for the timely diagnosis of glaucoma pathology, since changes in the RNFL follow only after alternation of the RGCs. As stated in the experimental studies conducted by Tao et al. [5] and Pitale et al. [6], vascular changes of the retina precede changes in the RGCs. As a result, the objective of our study was to determine whether more significant changes took place in eyes with pathological (higher than the statistical norm) IOP in the retinal vascular system or in the retinal nerve fiber layer (RNFL). If the former is the case, we aim to determine whether peripapillary changes in the VD or changes of the whole image (WI) of the VD are more significant. On the basis of the above correlation it shall then be possible to determine the importance of the individual parameters for timely diagnosis of glaucoma.

MATERIAL AND METHODS

The cohort comprised 26 women with an average age of 45 (22–70) years and 26 men with an average age of 43 (20–71) years, in total 104 eyes. In all eyes, IOP was greater than 21 mmHg (21–36 mmHg). The data were collected from February to April 2021 at the Eye Clinic JL (Prague, Czech Republic). The IOP values were the result of an average of three measurements using an Ocular Response Analyzer (ORA, Reichert). The inclusion criteria were as follows: visual acuity 1.0 with possible correction of less than ± 3 diopters, without changes in the visual field (glaucoma program-Medmont M700), no other ocular or neurological disease and no previous treatment of hypertensive glaucoma.

RNFL thickness and VD were measured with the aid of the instrument Avanti RTVue XR (Optovue). In the case of VD of the whole image and peripapillary, as well as peripapillary in eight segments (Figure 1): Inferior Temporal – IT (1); Temporal Inferior – TI (2); Temporal Superior – TS (3); Superior Temporal – ST (4); Superior Nasal – SN (5); Nasal Superior – NS (6); Nasal Inferior – NI (7) and Inferior Nasal – IN (8). In the case of RNFLc the VD (%) value was subtracted from the total value of RNFL, the principle is demonstrated in Figure 2. The following parameters were also evaluated: percentual representation of small (WI-VDs) or all vessels (WI-VDa) in the who-

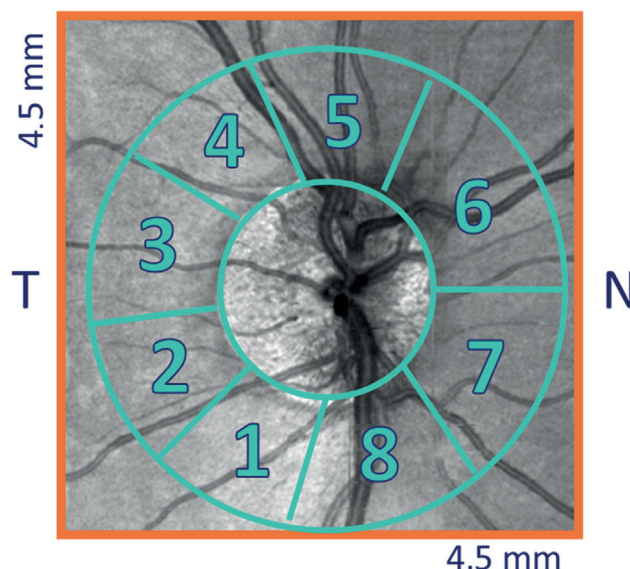


Figure 1. Identification of the individual peripapillary segments in which nerve fiber layer thickness (RNFL) and vascular density (VD) were assessed: Inferior Temporal – IT (1); Temporal Inferior – TI (2); Temporal Superior – TS (3); Superior Temporal – ST (4); Superior Nasal – SN (5); Nasal Superior – NS (6); Nasal Inferior – NI (7) and Inferior Nasal – IN (8)

le scanned image, percentual vascular representation in the peripapillary zone, of all vessels (PP-VDa) or only small vessels (PP-VDs).

The results were compared with VD and RNFL with the aid of a Pearson's correlation coefficient for assessment of the relationship between the selected parameters, and similarly the results of IOP with VD and RNFLc in the individual peripapillary segments.

RESULTS

Upon comparison of RNFL with IOP we determined a medium correlation ($r = -0.42$). After subtraction of VD from the RNFL values (RNFLc) in the individual segments, we did not determine any correlation.

We recorded a medium correlation also between PP-VD and PP-WI. The highest values were in WI-VDs ($r = -0.48$).

In VD in the individual segments, there was a weak correlation in segment 2, medium in segments 1, 4, 5, 6, 7 and 8 and none in segment 3. We recorded the highest value in segment IT ($r = -0.48$). Table 1 and 2.

DISCUSSION

The retinal vasculature is a three-layer network composed of the superficial retinal capillary plexus (SRCP), intermediate retinal capillary plexus (IRCP) and the deep retinal capillary plexus (DRCP). The SRCP sustains the RNFL, RGCs and the dendrites of the ON-RGCs in the inner plexiform layer (IPL). The IRCP then sustains the dendrites of the OFF-RGCs in the IPL and the amacrine cells in the inner nuclear layer (INL). The DRCP sustains

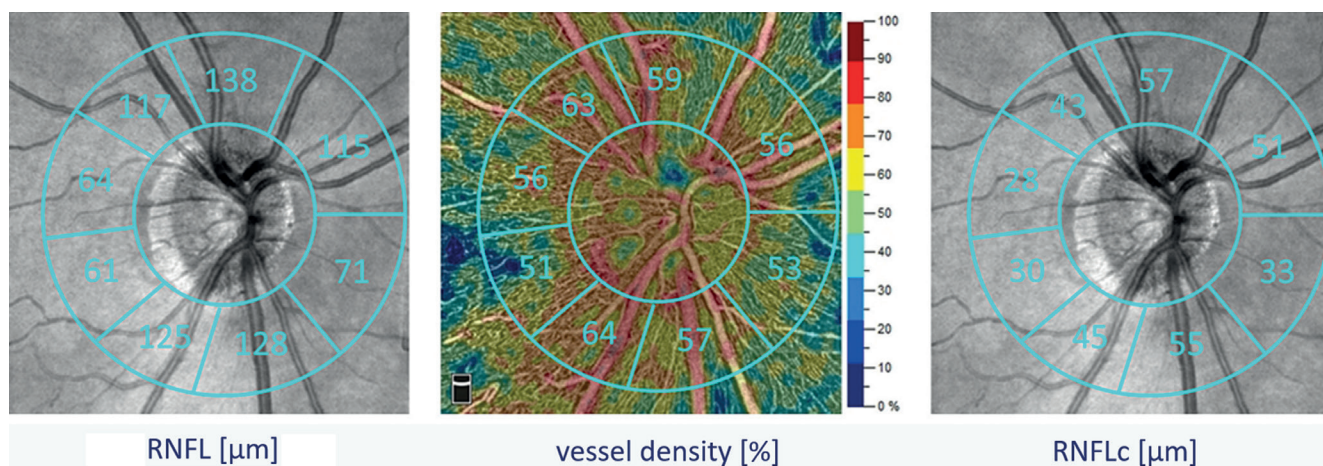


Figure 2. The principle of introducing a corrected nerve fiber layer thickness parameter (RNFLc), i.e., compensating for the nerve fiber layer thickness (RNFL) and vascular representation (VD) in a given segment volume

the bipolar cells (BC) and the horizontal cells (HC) in the outer plexiform layer (OPL) [11,12].

OFF-RGCs and especially their dendrites are more susceptible to an increase in IOP than ON-RGCs [13–16]. With reference to the fact that the primary blood supply for the OFF-RGCs and the IPL (dendrites of OFF-RGCs) is the

IRCP [11,12], the reduced local blood flow expected in the capillaries of the IRCP induced by IOP has a credible anatomical explanation [17].

As we saw in the introduction, Tao et al. and Pitale et al. in an experiment on mice demonstrated vascular changes in the retinal capillary plexuses following a temporary increase in IOP without damage being incurred to the RGCs [5,6]. Vascular changes in glaucoma have been found also in human medicine. Chen et al. determined reduced vascular density in the macular and peripapillary regions and in the whole image in eyes afflicted with glaucoma [18]. In addition to this, clinical studies on patients with glaucoma using optical coherence tomographic angiography (OCTA) state that temporary fluctuations of IOP may cause hypoxic damage, which leads to microvascular changes both on the retina and on the optic nerve papilla [19–21]. In this study we demonstrated a correlation between pathological values of IOP and VD (PP and WI) and the overall values of the RNFL. We did not record any correlation in the case of RNFLc. Our results are in accordance with the study conducted by Akil et al., who demonstrated statistically significant changes in

Table 1. Results of correlation analysis of intraocular pressure, vascular distribution (VD) and nerve fiber layer thickness (RNFL). Statistically significant dependencies are marked in red

	r	P
PP-VDa	-0.43	<0.01
PP-VDs	-0.45	<0.01
WI-VDa	-0.34	<0.01
WI-VDs	-0.48	<0.01
RNFL	-0.42	<0.01

PP-VDa – percentage of all vessels peripapillary, PP-VDs – percentage of small vessels peripapillary, WI-VDa – percentage of all vessels in the whole scanned image, WI-VDs – percentage of small vessels in the whole scanned image, RNFL – nerve fiber layer thickness

Table 2. Results of correlation analysis of intraocular pressure and parameters of vascular distribution (VD) and corrected nerve fiber layer thickness (RNFLc) in individual peripapillary segments. Statistically significant dependencies are marked in red

Segmenty	VD r	VD P	RNFLc r	RNFLc P
1-IT	-0.48	<0.01	-0.18	0.08
2-TI	-0.23	0.04	-0.03	0.81
3-TS	-0.12	0.23	-0.05	0.65
4-ST	-0.37	<0.01	-0.18	0.08
5-SN	-0.31	<0.01	-0.17	0.09
6-NS	-0.42	<0.01	-0.05	0.64
7-NI	-0.35	<0.01	-0.02	0.84
8-IN	-0.32	<0.01	-0.06	0.53

Inferior Temporal – IT; Temporal Inferior – TI; Temporal Superior – TS; Superior Temporal – ST; Superior Nasal – SN; Nasal Superior – NS; Nasal Inferior – NI and Inferior Nasal – IN

PP-VD in glaucoma patients in the pre-perimetric stage in comparison with a control group [22]. A high correlation between VD and RNFL was also observed by Yu et al [23] and Lee et al [24], who proposed that a decrease in VD in glaucoma is a secondary consequence of loss of RNFL. Triolo et al presented a similar view [25].

Our study demonstrated that vascular changes precede changes in the retinal nerve fiber layer. We believe that the primary changes are in VD, and secondary in the RNFL. The histological findings in the experiment also correspond to this view [4]. Similarly, Feher et al. determined that increased IOP initially compresses the microvessels of the optic nerve papilla, leading to ischemia of the tissue in question. In eyes with increased IOP there was a pronouncedly increased number of beta-adrenergic receptors [26].

Chen et al. demonstrated that in eyes with glaucoma the vessel density in the whole image (WI-VD) was lower than in healthy eyes in the macular ($38.5\% \pm 2.2\%$ vs. $43.2\% \pm 2.3\%$) and peripapillary regions ($43.8\% \pm 5.7\%$ vs. $53.3\% \pm 3.0\%$). Circumpapillary vessel density (cpVD) was also lower in eyes with glaucoma ($53.3\% \pm 7.0\%$ vs. $61.5\% \pm 3.2\%$) [27]. We also recorded similar results of VD in this study. Öztürk et al. also demonstrated decreasing values of VD with progression of glaucoma. The majority of peripapillary and macular VD parameters of the groups of pre-perimetric glaucoma and early glaucoma were lower than in healthy control groups ($P < 0.001$). There was no significant difference in RNFL between the groups of pre-perimetric and early glaucoma, but it was determined that most peripapillary and macular VD was

lower in the group with incipient glaucoma than in the pre-perimetric group ($P < 0.05$) [28]. Similar results were found also by Yarmohammadi et al. With the aid of OCTA they determined that vessel density has a similar diagnostic precision as measurement of the thickness of the RNFL [19].

Our results of uncorrected RNFL demonstrated a similar conclusion. However, after subtracting the VD values from the total RNFL (RNFLc), the results differ significantly. We did not find any similar studies in the literature in which the authors determined a relationship between IOP and RNFL after correction of VD. Mansoori T. et al. presented a study comparing the density of the radial peripapillary capillaries (RPC) in healthy eyes and patients with primary open-angle glaucoma with the aid of OCTA. They discovered that density of the RPC was lower in the inferotemporal ($p = 0.002$) and superotemporal ($p = 0.008$) sectors in the group of POAG in comparison with healthy control subjects [29]. Our results pointed to the highest correlation in the IT segment ($r = -0.48$).

CONCLUSION

Of cardinal importance for glaucoma is timely diagnosis and commencement of treatment. We demonstrated that the density of the vascular supply of small vessels of the whole image (WI-VDs) correlates most with increasing IOP. We found a similar correlation also in VD in the IT peripapillary segment. As a result it is possible to classify OCT angiography in one of the first places, and to interpret its results together with those of other tests used in the diagnosis of the pathology.

REFERENCES

- Burgoyne CF, Downs JC, Bellezza AJ, Suh JK, Hart RT. The optic nerve head as a biomechanical structure: a new paradigm for understanding the role of IOP-related stress and strain in the pathophysiology of glaucomatous optic nerve head damage. *Prog Retin Eye Res.* 2005;24:39-73.
- Weinreb RN, Aung T, Medeiros FA. The pathophysiology and treatment of glaucoma: a review. *Jama.* 2014;311:1901-1911.
- Gedde SJ, Vinod K, Wright MM, et al. Primary Open-Angle Glaucoma Preferred Practice Pattern®. *Ophthalmology.* 2021;128:71-150.
- Soto I, Oglesby E, Buckingham BP, et al. Retinal Ganglion Cells Downregulate Gene Expression and Lose Their Axons within the Optic Nerve Head in a Mouse Glaucoma Model. *J Neurosci.* 2008;28:548-561.
- Tao X, Sigireddi RR, Westenskow PD, Channa R, Frankfort BJ. Single transient intraocular pressure elevations cause prolonged retinal ganglion cell dysfunction and retinal capillary abnormalities in mice. *Exp Eye Res.* 2020;201:108296. doi: 10.1016/j.exer.2020.108296
- Pitale PM, Shen G, Sigireddi RR, et al. Selective vulnerability of the intermediate retinal capillary plexus precedes retinal ganglion cell loss in ocular hypertension. *Front Cell Neurosci.* 2022;16:1073786. doi: 10.3389/fncel.2022.1073786
- Kral J, Lestak J, Nutterova E. OCT angiography, RNFL and visual field at different values of intraocular pressure. *Biomed Rep.* 2022 May;16(5):36. doi: 10.3892/br.2022.1519
- Lešták J, Füs M, Král J. The Relationship Between the Thickness of cpRNFL in Segments and Intraocular Pressure. *Clin Ophthalmol.* 2022;16:1-7.
- Lešták J, Füs M, Král J. Axons of retinal ganglion cells on the optic nerve disc following vessel density correction at different IOP values. *Exp Ther Med.* 25; 261, 2023. doi: 10.3892/etm.2023.11960
- Lestak J, Füs M, Pitrova S. Peripapillary retinal nerve fiber layer following vessel density correction at different IOP values. *Biomed Pap Med Fac Univ Palacky Olomouc Czech Repub.* 2024;17. doi: 10.5507/bp.2024.001
- Usui Y, Westenskow PD, Kurihara T, et al. Neurovascular crosstalk between interneurons and capillaries is required for vision. *J Clin Invest.* 2015;125:2335-2346. doi: 10.1172/JCI80297
- Nian, S., Lo ACY, Mi Y, Ren K. Neurovascular unit in diabetic retinopathy: pathophysiological roles and potential therapeutic targets. *Eye Vis (Lond).* 2021;8:15. doi: 10.1186/s40662-021-00239-1
- Della Santina L, Inman DM, Lupien CB, Horner PJ, Wong ROL. Differential progression of structural and functional alterations in distinct retinal ganglion cell types in a mouse model of glaucoma. *J Neurosci.* 2013;33:17444-17457. doi: 10.1523/JNEUROSCI.5461-12.2013
- El-Danaf RN, Huberman AD. Characteristic patterns of dendritic remodeling in early-stage glaucoma: evidence from genetically identified retinal ganglion cell types. *J Neurosci.* 2015;35:2329-2343. doi: 10.1523/JNEUROSCI.1419-14.2015
- Ou Y, Jo RE, Ullian EM, Wong ROL, Della Santina L. Selective vulnerability of specific retinal ganglion cell types and synapses after transient ocular hypertension. *J Neurosci.* 2016;36:9240-9252. doi: 10.1523/JNEUROSCI.0940-16.2016
- Sabharwal J, Seilheimer RL, Tao X, Cowan CS, Frankfort BJ, Wu SM. Elevated IOP alters the space-time profiles in the center and surround of both ON and OFF RGCs in mouse. *Proc Natl Acad Sci USA.* 2017;114:8859-8864. doi: 10.1073/pnas.1706994114

17. Campbell JP, Zhang M, Hwang TS, et al. Detailed Vascular Anatomy of the Human Retina by Projection-Resolved Optical Coherence Tomography Angiography. *Sci Rep.* 2017;10:7:42201. doi: 10.1038/srep42201
18. Chen HS, Liu CH, Wu WC, Tseng HJ, Lee YS. Optical Coherence Tomography Angiography of the Superficial Microvasculature in the Macular and Peripapillary Areas in Glaucomatous and Healthy Eyes. *Invest Ophthalmol Vis Sci.* 2017;58:3637-3645.
19. Yarmohammadi A, Zangwill LM, Diniz-Filho A, et al. Optical coherence tomography angiography vessel density in healthy, glaucoma suspect and glaucoma eyes. *Invest Ophthalmol Vis Sci.* 2016;57:451-459. doi: 10.1167/iovs.15-18944
20. Jia Y, Simonett JM, Wang J, et al. Wide-field OCT angiography investigation of the relationship between radial peripapillary capillary plexus density and nerve fiber layer thickness. *Invest Ophthalmol Vis Sci.* 2017;58:5188-5194. doi: 10.1167/iovs.17-22593
21. Liu L, Edmunds B, Takusagawa H L, et al. Projection-resolved optical coherence tomography angiography of the peripapillary retina in glaucoma. *Am J Ophthalmol.* 2019;207: 99-109. doi: 10.1016/j.ajo.2019.05.024
22. Akil H, Huang AS, Francis BA, Sadda SR, Chopra V. Retinal vessel density from optical coherence tomography angiography to differentiate early glaucoma, pre-perimetric glaucoma and normal eyes. *PLoS ONE.* 2017;12:1-12.
23. Yu PK, Cringle SJ, Yu DY. Correlation between the radial peripapillary capillaries and the retinal nerve fibre layer in the normal human retina. *Exp Eye Res.* 2014;129:83-92. doi: 10.1016/j.exer.2014.10.020
24. Lee EJ, Lee KM, Lee SH, Kim TW. OCT Angiography of the peripapillary retina in primary open-angle glaucoma. *Invest Ophthalmol Vis Sci.* 2016;57:6265-6270. doi: 10.1167/iovs.16-20287
25. Triolo G, Rabiolo A, Shemonski ND, et al. Optical Coherence tomography angiography macular and peripapillary vessel perfusion density in healthy subjects, glaucoma suspects, and glaucoma patients. *Invest Ophthalmol Vis Sci.* 2017;58:5713-5722. doi: 10.1167/iovs.17-22865
26. Feher J, Pescosolido N, Tranquilli Leali FM, Cavallotti C. Microvessels of the human optic nerve head: Ultrastructural and radioreceptorial changes in eyes with increased IOP. *Can J Ophthalmol.* 2005;40:492-498.
27. Chen HS, Liu CH, Wu WC, Tseng HJ, Lee YS. Optical Coherence Tomography Angiography of the Superficial Microvasculature in the Macular and Peripapillary Areas in Glaucomatous and Healthy Eyes. *Invest Ophthalmol Vis Sci.* 2017;58:3637-3645. doi: 10.1167/iovs.17-21846
28. Öztürk C, Güngör SG, Ekşioğlu Ü, Sezenöz AS, Çolak M. Peripapillary and macular vascular densities in healthy, ocular hypertensive, and different stages of glaucomatous eyes. *Int J Ophthalmol.* 2023;18:16(12):2018-2026.
29. Mansoori T, Sivaswamy J, Gamalapati JS, Balakrishna N. Radial Peripapillary Capillary Density Measurement Using Optical Coherence Tomography Angiography in Early Glaucoma. *J Glaucoma.* 2017;26:438-443.