

ORBITAL EXENTERATION IN PATIENT WITH METASTATIC CHOROIDAL MELANOMA

SUMMARY

Introduction: Uveal melanoma is the most common primary intraocular tumour in adults in Caucasians and in 75% is arising from choroid. It threatens not only the patient's loss of vision and eye, but also 50% of patients after 5-year interval after therapy die due to distant metastases. The treatment of small and medium-sized melanoma are methods preserving eye globe. Almost half of the total number of patients is still unavoidable enucleation. Considerably rarer is indicated exenteration of an orbit. These tumors metastasize only hematogenous, while the most frequent place of localization of distant metastases is the liver. Generalized disease prognosis is poor, and our current treatment options in this stage are ineffective.

Material and methods: Case report of 59 years old patient with choroidal melanoma stage T4 N1 M1 massively infiltrating the orbit. At the time of diagnosis of the primary tumor distant metastases were present. The patient underwent exenteration of the orbit and systemic chemotherapy.

Discussion: Although choroidal melanomas with extrascleral extension and infiltration into the orbit have no better prognosis after exenteration of the orbit, surgery is providing us local tumour control. Good cosmetic effect after this mutilating procedure is offered by individually made prosthesis (epithesis). All patients with uveal melanoma require lifelong dispensation, distant metastases may occur even after many years. In the treatment of generalized disease is available systemic chemotherapy and immunotherapy only palliative. The best effect on survival has complete surgical resection of single metastasis. Uveal melanoma has a different genetic profile as cutaneous melanoma. The biological nature of uveal melanoma seems to be the key to determining risk patients, as well as the development of targeted systemic therapy.

Conclusion: Treatment of patients with generalized large uveal melanoma with extrascleral extension is difficult. A better understanding of biological interest may be the key to the detection of patients at higher risk of distant metastases formation, and to an effective systemic treatment.

Key words: large uveal melanoma, extrascleral extension, orbital exenteration, the treatment of generalized disease

Čes. a slov. Oftal., 72, 2016, No. 3, p. 92–96

INTRODUCTION

Uveal melanoma is the most common primary intraocular tumour in adults of the Caucasian race. The peak incidence is in patients aged around 60 years, without a predilection for either sex. Tumours localised in the vicinity of the posterior pole may be manifested by relatively early blurring of vision, floating opacities in front of the eye or curvature of vision due to subretinal fluid. Choroidal melanomas localised pre-equatorially and especially melanomas of the corpus ciliare are generally diagnosed later. Tumours originating from the iris have a good prognosis, are generally diagnosed early due to their localisation and rarely metastasise, since histologically they mainly comprise fusiform cells (2, 4, 5, 13, 14).

At the time of determination of the diagnosis, distant metastases which could be detected by the examination methods available at present are not present in the majority of patients. Uveal melanoma metastasises exclusively haematogenously, in which the uveal does not contain lymphatic blood vessels. In 90% of cases the first localisation of a distant metastasis is the liver, and in approximately half of patients this remains the sole localisation. Further localisations include the lungs, bone, skin, in rare cases the

brain and uveal tract of the other eye. The prognosis of the generalised pathology is negative, on average survival is 6 months. The cause of death is most frequently liver failure or obstructive jaundice (4, 5, 20).

From the perspective of the ophthalmologist, the therapeutic procedure covers local control of the tumour and in the case of the presence of distant metastases also treatment of the systemic pathology in co-operation with an oncologist. Treatment of the tumour itself depends on a number of factors, in addition to size (largest diameter and elevation) and localisation of the tumour (if it has its origin in the iris, ciliary muscle, choroid and similarly proximity to the macula and disc of the optic nerve), as well as the presence of neovascular glaucoma, visual function of the afflicted and other eye, and last but not least the overall condition and wishes of the patient. In the case of melanomas of small and medium size we attempt to preserve the eyeball, and if possible also sight, wherein at present in Slovakia the only radiotherapeutic option is stereotactic radiosurgery on a linear accelerator. Abroad procedures of brachytherapy, Leksell gamma knife and proton therapy are also used (5, 12, 15, 16, 20).

Upon a finding of large melanoma (diameter > 15 mm,

Justusová P., Štubňa M.,
Veselovský M., Lipková B.

Department of Ophthalmology, University
Hospital and Clinic, Žilina
Head physician: MUDr. Michal Štubňa,
PhD.

*The case report was presented at the 8th
Bilateral Slovak-Czech Ophthalmology
Symposium, held in Žilina from 16-18
April 2015*

*The authors of the study declare that no
conflict of interest exists in the compilation,
theme and subsequent publication of this
professional communication, and that it
is not supported by any pharmaceuticals
company.*



MUDr. Pavlína Justusová
Očné oddelenie FNŠP Žilina
Vojtecha Spanyola 43
012 07 Žilina
e-mail: pjustusova@gmail.com

thickness > 10 mm) and in the case of painful and blind eyeballs we proceed to enucleation. If the tumour grows massively transsclerally, exenteration of the orbit is indicated, i.e. removal of the entire content of the orbit, including the periorbit and eyelids. In the case of a smaller degree of extrascleral spread some authors choose subtotal exenteration, in which the eyelids and conjunctiva are preserved for a better cosmetic effect. Extended exenteration is indicated in the case of invasion of the tumour into the bone, and incorporates its resection (19,21).

With regard to the profile of genetic expression, uveal melanomas are divided into class 1 (with low risk) and class 2 (with high risk). Class 2 melanomas are characterised by chromosome abnormalities in the 3rd and 8th chromosome, which are linked with larger dimensions of the tumour, a higher risk of the incidence of metastases and a more negative prognosis. However, distant metastases also occur in a small percentage of patients from class 1. At present research is focusing on detecting biomarkers on the basis of which we will be better able to predict the prognosis also in patients without chromosome abnormalities. The molecular profile of uveal melanomas will in future probably be significant not only from the perspective of the patient's prognosis and therapeutic procedure, but also in the detection of micrometastases and in systemic chemotherapy and immunotherapy (6).

CASE REPORT

A man of Caucasian racial origin aged 59 years first reported to our outpatient clinic in February 2014. He stated complaints with his left eye persisting for approximately 1 year, consisting of pain and deterioration of vision. On the fundus of the left eye there was a protruding greyish brown formation with grains of orange pigment on the surface with a diameter of approx. 5 mm, and beneath it exudative retinal detachment. The finding was evaluated as suspected choroidal melanoma and the patient was sent immediately to the Onco-ophthalmological Outpatient Department.

However, the patient did not go to this department for examination, and reported to our centre again almost a full year later in January 2015, stating that his left eye had "bloated" and was painful. The left eyeball was deviated upwards and nasally, with limited mobility (fig. 1, 2), beneath the skin of the lower eyelid there was palpable resistance and the pigment formation on the fundus had at least doubled in size (fig. 3). Vision in the left eye was hand movement, intraocular pressure bilaterally 18 mmHg. Vision in the right eye was 6/6 with hypermetropic correction, the finding on the anterior section and ocular fundus of the right eye within the norm.

We performed fluorescence angiography, in which the finding was typical of a choroidal melanoma. In the early phases a double circular pattern was displayed (fig. 4), later seeping hot spots (fig. 5) from which the contrast substance seeped and accumulated in the area of the tumour in the late phases – staining (fig. 6). CT confirmed extraocular growth of the tumour with invasion into the extraocular

muscles (m. rectus temporalis, m. obliquus inferior and m. rectus inferior) and into the optic nerve (fig. 7). In February 2015 the patient underwent PET-CT (positron emission tomography), in which lesions of the character of metastases into the liver, lungs and thoracic and abdominal lymphatic nodes.

In March 2015 exenteration of the left orbit was performed at the Department of Ophthalmology of the Faculty of Medicine, Comenius University and Ružinov University Hospital. The size of the intraocular tumour was relatively small with regard to the massive extraocular growth (fig. 8). The histological examination confirmed malignant choroidal melanoma, predominantly epitheloid, less fusiform B-type, with massive invasion via the sclera into the peribulbar tissues of the orbit. Postoperative healing took place without complications (fig. 9), and after the healing of the orbital cavity an individual silicon epithesis was produced for the patient with prosthesis of the eye attached to the glasses frame (fig. 10).

The oncologist indicated palliative adjuvant chemotherapy. The patient underwent the first 6 cycles of dacarbazine from April to September 2015 with relatively good tolerance, and a further cycle of chemotherapy with carboplatin and cisplatin was commenced. At PET-CT in November new deposits appeared in both lobes of the prostate, progression is the size of a hepatic lesion. The local finding in the orbital cavity is so far without signs of recurrence of the pathology.

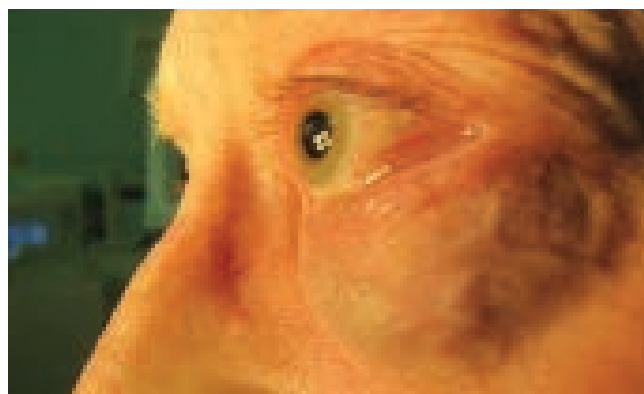


Fig. 1 Visible growth of tumour beneath the lower eyelid

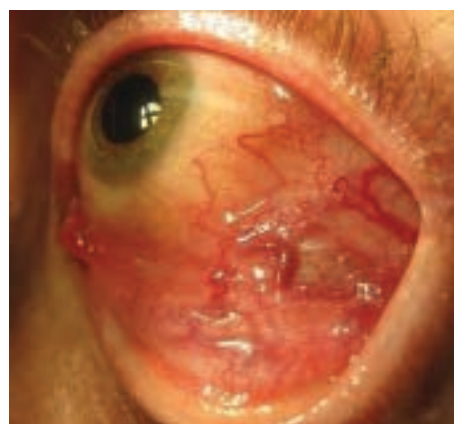

Fig. 2 Deviation of eyeball upwards nasally and dilated supplying blood vessels

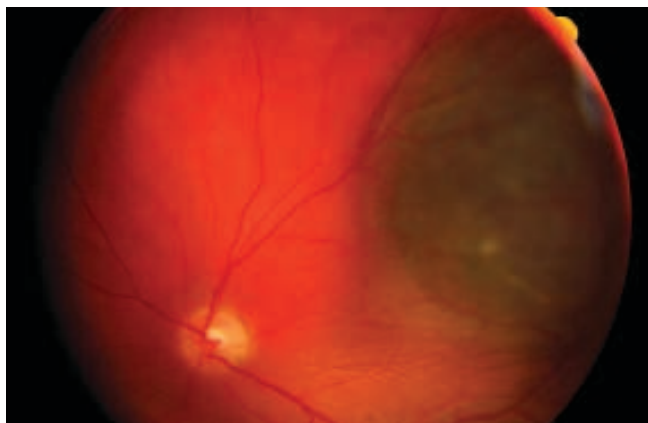


Fig. 3 Finding on posterior pole

DISCUSSION

In generalised uveal melanoma, exenteration of the orbit is considered a palliative procedure which if sufficiently radical ensures good local control of the tumour. Regressions of the tumour in the orbit have been described following conservative therapy. In patients without metastases survival after exenteration as such is no different in comparison with the conservative procedure. As a result, in the case of anterior extrascleral spread some authors prefer local resec-

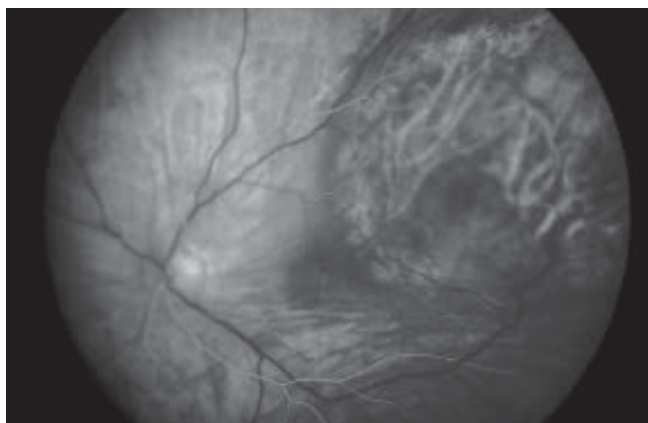


Fig. 4 Arterial phase of FAG – double circular pattern

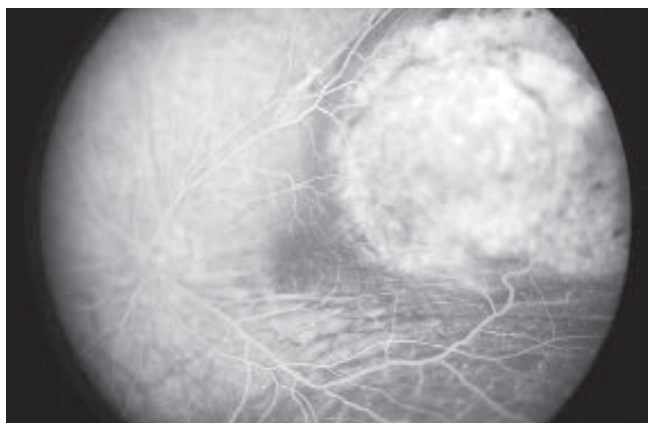


Fig. 5 Hot spots in 1st minute of FAG

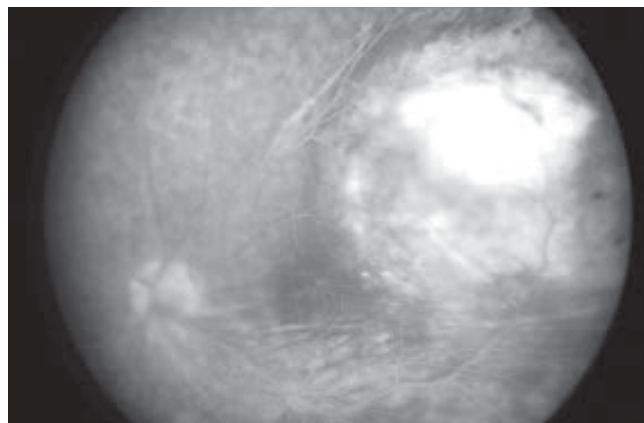


Fig. 6 Accumulation of fluoresceine (staining) in later phases

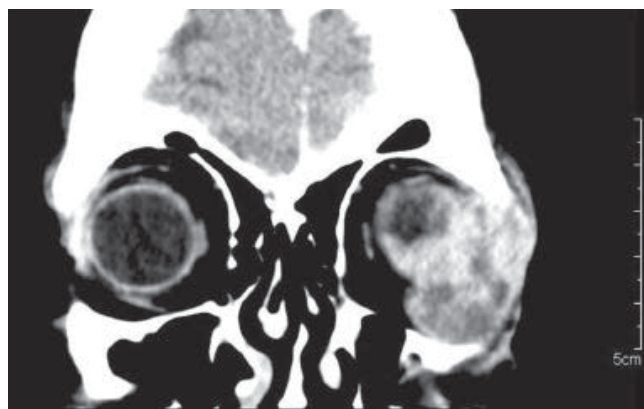


Fig. 7 Massive infiltration of tissues of orbit on CT

tion supplemented by radiotherapy (3, 9, 11, 19, 21). Our patient had massive growth of melanoma into the orbit in a painful, practically blind eyeball, and as a result we proceed to exenteration in co-operation with an otorhinolaryngologist. At the time of observation the orbital cavity is without signs of recurrence of the pathology.

Prognostic factors of uveal melanoma include the type of cells according to Callender, size, transscleral spread, mitotic activity, location of anterior edge of tumour and invasion into the optic nerve (4, 16). In Slovakia the profiling of genetic expression is not yet available. In our patient this

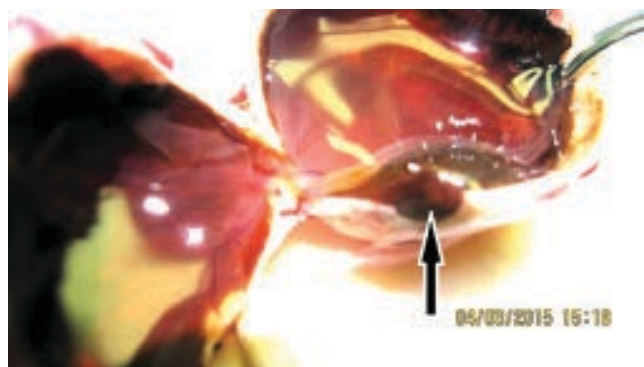


Fig. 8 Relatively small intraocular melanoma (arrow indicates tumour deposit)

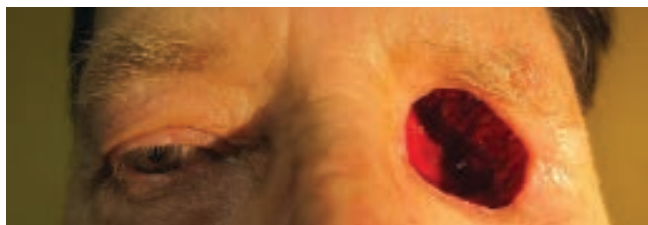

Fig. 9 Patient after exenteration




Fig. 10 Epithesis affixed to frame of glasses

concerned a large melanoma with growth extrasclerally and into the optic nerve, histologically predominantly epitheloid, less fusiform B type, which attests to the aggressive character of the tumour.

At the time of determination of the diagnosis, distant metastases were relatively rare, in only 2-3% of patients. For the occurrence of metastases it is therefore necessary to have approximately 30 divisions (of cell cycles) of the tumour, which takes approximately 2.2 years (5). However, at the time when our patient decided in favour of diagnosis and treatment of his complaints, these had persisted for 2 years, which means that the pathology had probably also been present for the same period. At the first PET-CT metastases into the lymph nodes, liver and lungs were displayed, and after 6 months also further lesions of the character of metastatic deposits in the prostate.

A number of therapeutic modalities are used for the treatment of metastasising uveal melanoma, but to date none of the options of systemic treatment had achieved a significant benefit for survival. The longest median of survival was in patients with a solitary metastasis in the liver or other location, in which complete surgical resection was possible. Unfortunately this relates to less than 10% of patients. Frenkel et al. succeeded in extending survival by a multiple of 3.7 (5, 7, 8) in a group of 74 patients following resection of a single metastasis in the liver without adjuvant therapy. In the case of our patient, this possibility did not exist due to the presence of several metastatic deposits.

Chemotherapy as treatment of metastasising uveal melanoma has been tested with the use of several chemotherapeutic drugs and combinations thereof, in which the longest survival (median 14 months) so far was achieved by Pföhler et al. in a group of 14 patients, with the use of a combination of treosulfan and gemcitabine (22). Upon the use of a combination of dacarbazine, carmustine, cisplatin and tamoxifen, in which the response in metasta-

sising skin melanoma was 33%, the response in the case of metastasising uveal melanoma was only 10% (1). From the beginning of systemic chemotherapy with dacarbazine, cisplatin and carboplatin up to the time of writing this article, our patient has survived for 12 months.

Ipilimumab is a monoclonal antibody acting against the anti-cytotoxic T-lymphocyte antigen 4 (CTLA-4), which is used as immunotherapy of advanced (non-resectable or metastasising) skin melanoma. As yet there is no relevant data on its effect on uveal melanoma. The mechanism of the effect is blockade of the antigen CTLA-4 on T-lymphocytes, which acts as a negative regulator, and can thereby strengthen the response of T-lymphocytes against tumour cells (17).

Uveal melanoma has a specific genetic profile, which makes it an attractive candidate for discovering targeted molecular therapy. Therapy should be focused on regulation of the cell cycle, inhibition of the molecule influencing invasiveness and metastasising, and inhibition of angiogenesis. In contrast with skin melanomas, BRAF mutation is exceptional in uveal melanomas. The majority of uveal melanomas (more than 75%) manifest mutation in the GNAQ and GNA11 genes, which code the heterotrimeric proteins bonding guanine nucleotides to the cell surface and play a role in intracellular signal pathways (18, 23).

In addition to systemic therapy, there are also local methods of treatment of metastases, namely chemoembolisation, immunoembolisation, intra arterial chemotherapy and radioembolisation (5).

An integral component of patient care following a mutilating procedure such as exenteration of the orbit is the impact of the cosmetic effect of surgery on the patient's social life. After exenteration the orbital cavity granulates and preepithelises mostly within 3 months. Some authors cover the cavity immediately following exenteration with a skin flap, in which the resulting healed cavity is deeper than in the case of spontaneous healing (10, 19). Each patient has the right to individual healing of the epithesis, which facilitates the patient's return to social life. Epithesis of the eye in Slovakia may be prescribed by an ophthalmologist on a medical prescription, and is paid for in full by all three health insurance companies. An epithesis was produced for our patient, affixed to the glasses frame with good cosmetic effect.

CONCLUSION

Treatment of patients with a generalised large uveal melanoma is demanding. In the case of massive extrascleral growth, exenteration of the orbit ensures good local control of the tumour, even despite the fact that a radical surgical intervention here has not demonstrated any benefit for patient survival. Further research is necessary, focusing on the biological character of uveal melanoma, which could provide the key to detecting patients with a higher risk of the formation of distant metastases, as well as effective systemic therapy.

1. **Albert, D. M., Ryan, L. M., Borden, E. C.:** Metastatic ocular and cutaneous melanoma: a comparison of patient characteristics and prognosis. In *Arch Ophthalmol*, 1996; 114(1): 107.
2. **Baráková, D., et al.:** Nádory oka, Grada Avicenum, Praha, 2002, 152 s.
3. **Bianco, G.:** Diagnosis and treatment of orbital invasion in uveal melanoma. *Can J Ophthalmol*, 2004; 39: 388–396.
4. **Bowling, B.:** Kanski's Clinical Ophthalmology, 8th edition. Elsevier, 2016, 917 p.
5. **Damato, B., Singh, A. D.:** Clinical Ophthalmic Oncology, Uveal Tumours, 2. vydanie. Springer, 2014, 382 p.
6. **Field, M. G., Decatur, C. R., Kurtenbach, S.:** PRAME as an Independent Biomarker for Metastasis in Uveal Melanoma. *Clinical Cancer Research*. 2016; 22(5): 1234–42.
7. **Fournier, G. A., Albert, D. M., Arrigg, C. A., et al.:** Resection of solitary metastasis. Approach to palliative treatment of hepatic involvement with choroidal melanoma. *Arch Ophthalmol*, 1984; 102(1): 80.
8. **Frenkel, S., Nir, I., Hendler, K., et al.:** Long-term survival of uveal melanoma patients after surgery for liver metastases. *Bri J Ophthalmol*, 2009; 39(8): 1042.
9. **Furdová, A.:** Extrasklerálne prerastanie malígneho melanómu choroidey po endoresekcii. *Čes a slov Oftalmol*, 2012(4): 163–168.
10. **Furdová, A., Ferková, A., Krásnik, V., et al.:** Exenterácia očnice pre malígný melanóm choroidey v štádiu T4; možnosti epitetického riešenia. *Čes a slov Oftalmol*, 2015(3): 150–156.
11. **Furdová, A., Chynoranský, M., Krajčová, P.:** Orbital melanoma. *Bratislava Medical Journal – BLL*. 2011; 112 (8): 466–468.
12. **Furdová, A., Strmeň, P., Šramka, M.:** Complications in patients with uveal melanoma after stereotactic radiosurgery and brachytherapy. In *Bratislava Medical Journal – BLL*. 2005, 106(12): 401–406.
13. **Furdová, A., Oláh, Z.:** Malígný melanóm v uveálnom trakte. Bratislava, Asklepios, 2002, 172 s.
14. **Furdová, A., Oláh, Z.:** Nádory oka a okolitých štruktúr. Brno, CERM, 2010, 152 s.
15. **Furdová, A., Šramka, M.:** Uveal malignant melanoma and stereotactic radiosurgery. Saarbrücken: LAP LAMBERT Academic Publishing, 2014, 181 s.
16. **Furdová, A., Šramka, M., Waczulíková, I.:** Stereotaktická rádiochirurgia (LINAC) uveálnych melanómov; postradiačné komplikácie. *Čes a slov Oftalmol*, 2015; (3): 134–142.
17. **Hodi, F. S., O'Day, S. J., McDermott, D. F., et al.:** Improved survival with ipilimumab in patients with metastatic melanoma. *New England Med*, 2010; 363(8): 711.
18. **Onken, M. D., Worley, L. A., Long, M. D., et al.:** Oncogenic mutations in GNAQ occur early in uveal melanoma. *Invest Ophthalmol Vis Sci*, 2008; 49(12): 5230.
19. **Migliori, M. E.:** Enucleation, Evisceration and Exenteration. In *Albert & Jakobiec's Principles & Practice of Ophthalmology*. Philadelphia, Elsevier, 2008, 3519–28.
20. **Nathan, P., Cohen, V., Coupland, S., et al.:** Uveal Melanoma UK National Guidelines. *Eur J Cancer*, 2015; 51(16): 2404–12.
21. **Perry, J. D., Singh, A. D.:** Clinical Ophthalmic Oncology, Orbital Tumours. Berlin, Springer, 2014, 221 p.
22. **Pfohler, C., Cree, I. A., Ugurel, S. et al.:** Treosulfan and gemcitabine in metastatic uveal melanoma patients: results of a multicenter feasibility study. *Anticancer drugs*, 2003; 14(5): 337.
23. **Van Raamsdonk, C. D., Griewank, K. G., Crosby, M. B. et al.:** Mutations in GNA11 in uveal melanoma. *New England Med*, 2010; 363(23): 2191.