

# INCIDENCE OF PSEUDOEXFOLIATION SYNDROME AND GLAUCOMA IN A SET OF MORE THAN 14 000 EYES OF CATARACT-OPERATED PATIENTS

Lachovská S., Kristian P., Krowicka JH.

Gemini Eye Clinic Ostrava, Czech Republic

*The authors of the thesis declare that the origin and topic of the professional message and its publication are not in conflict of interests and are not supported by any pharmaceutical company. The work was not assigned to another journal or published elsewhere, except as congress abstracts.*

Received: 21 August 2021

Accepted: 5 January 2022

Available on-line: 21 March 2022



MUDr. Silvie Lachovská  
Gemini oční klinika Ostrava  
Ke Kamenině 356/15  
711 00 Ostrava-Hrušov  
E-mail: silvie.lachovska@gemini.cz

## SUMMARY

**Purpose:** Evaluation of the incidence of pseudoexfoliation (PEX) syndrome and glaucoma in cataract patients operated at our Clinic, with an analysis of possible complications.

**Methodology:** Retrospective evaluation of medical records of PEX syndrome patients who have undergone cataract surgery at the Gemini Eye Clinic Ostrava-Hrušov was undertaken. The study period was from November 2016 to April 2021. The evaluated parameters were the incidence of PEX syndrome, age and gender of patients, intraocular pressure (IOP) before the surgery, pre-existing therapy of previously diagnosed secondary glaucoma and the occurrence of perioperative complications.

**Results:** In the study period of 4.5 years, out of the total number of 14 167 operated eyes with cataracts there were 852 eyes of 689 patients with PEX syndrome diagnosed at our Clinic, i.e. 6.0%. The mean age was 76.9 years, the median 77 years, range 54–100 years. The observed pathology was more common in women at a ratio of 1.84: 1 (552: 300). Elevation of IOP above 21 mmHg was recorded in 118 eyes, in 14 of them IOP reached values over 30 mmHg. Diagnosed and long-term treated secondary glaucoma was confirmed by 153 patients (204 eyes), out of which 22 eyes have undergone antiglaucoma laser (19 eyes) and / or surgery (5 eyes) in the anamnesis. Perioperatively, we recorded the following pathological findings accompanying the occurrence of PEX syndrome in 231 eyes. Most often it was poor artificial mydriasis (189 eyes), then subluxation of the lens (31 eyes) or zonular fragility (17 eyes). To reduce the risk of perioperative and postoperative complications, implantation of a capsular tension ring was indicated in 20 eyes. Complications during the procedure occurred in 11 eyes, of which 8 eyes were diagnosed with advanced cataract.

**Conclusion:** PEX syndrome and glaucoma are relatively common diseases that can complicate the lives of patients and eye surgeons. The incidence of PEX syndrome in our cataract patients was 6%. Proper diagnosis of this disease is important not only for the possible occurrence of numerous complications during and after cataract surgery, but also for the possible presence of secondary glaucoma. It also serves to detect possible involvement of the contralateral eye. In addition, due to the involvement of practically all tissues in the body, the patient is endangered by numerous, especially vascular comorbidities. For these reasons, we find it appropriate that these patients are observed by other healthcare specialists.

In our experience, early indication of cataract surgery is important to achieve a lower degree of zonular fragility and a softer lens core. In addition, lower levels of proinflammatory pseudoexfoliation material occur in the anterior segment of the eye in the early stages, which may have a beneficial effect on the postoperative healing

**Key words:** pseudoexfoliation syndrome, pseudoexfoliation glaucoma, secondary glaucoma, cataract, phacoemulsification, complications

Čes. a slov. Oftal., 78, 2022, No. 2, p. 56–62

## INTRODUCTION

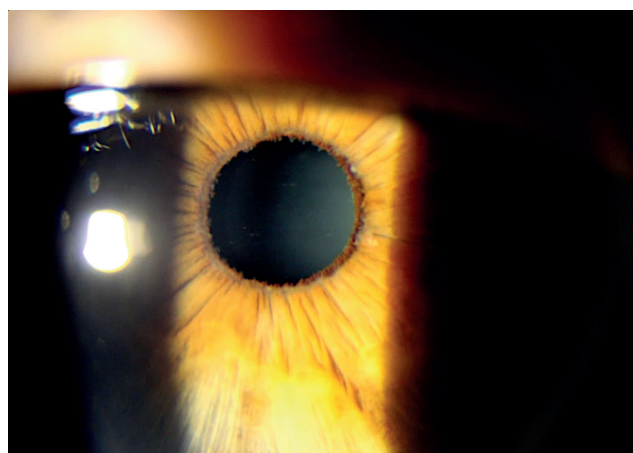
Pseudoexfoliation (PEX) syndrome is an ocular manifestation of a systemic disorder with a certain genetic basis (autosomal dominant inheritance with incomplete penetration) [1,2]. Currently, several genes have been identified that may be involved in the development of PEX syndrome

(LOXL 1, CACNA 1A) [3]. The disease rarely occurs before the age of 50. The prevalence of 50–59 years is reported to be only 0.4% [3]. The incidence and severity of the disease increase rapidly after the 6th decade of life [4]. It is more common in women, but there is a higher incidence of PEX-induced glaucoma in men [3]. Worldwide, up to 70 million people suffer from PEX syndrome, with geographi-

cal location playing a significant role in incidence. The highest incidence is usually reported in Scandinavia and Greece [3]. The disease is characterised by the formation of pathological pseudoexfoliation masses. Histologically, it is an amorphous eosinophilic microfibrillar material (Figure 1) [1], which is found in the tissues of the eye, ocular adnexa, orbit, but also in the vascular system and visceral organs of the body (e.g. lungs, heart, kidneys, liver, skin) [3]. There are studies showing a link between PEX syndrome and general diseases (e.g. stroke, Alzheimer's disease, coronary heart disease, aortic aneurysm, homocystinuria) [5,6]. Deposits of this material are evident on the cornea, iris (Figure 2), lens, ciliary protrusions, zonular apparatus, and trabecular meshwork of the anterior chamber angle [1]. PEX may occur both unilaterally and bilaterally with lateral asymmetry [7]. In the early stages of the disease, it can be easily overlooked when examined on a slit lamp (Figure 3) [4]. At the lens capsule, this grey-white material typically forms two concentric circles with a central

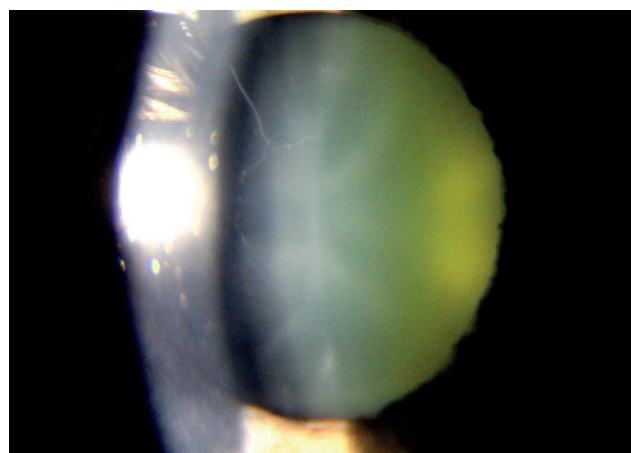


**Figure 1.** Histological image of amorphous eosinophilic microfibrillar tree-like material on the surface of the anterior lens capsule

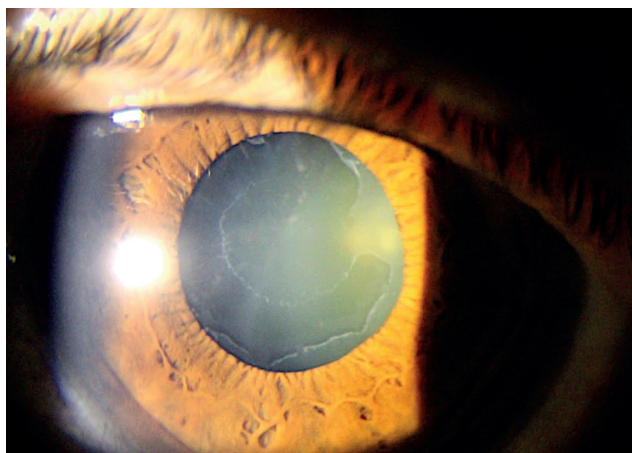


**Figure 2.** Deposits of pseudoexfoliation material at the pupillary margin of the iris

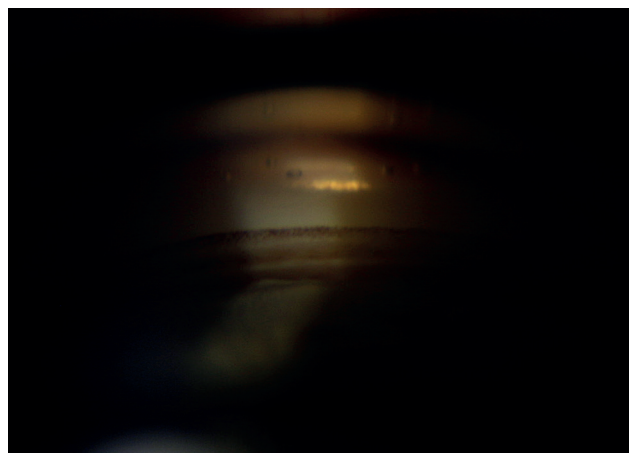
zone in the area of the unexpanded pupil (Figure 4) [3]. Atrophy of the iris, pigmentation of its anterior surface and pigmentation of the anterior chamber angle structures are also evident. A typical gonioscopic finding is the formation of a hyperpigmented Sampaolesi line before the Schwalbe line (Figure 5) [4]. The Sampaolesi line, together with deposits of material in the pupillary margin of the iris and deposits on the anterior capsule, is one of the most specific symptoms of PEX syndrome in pseudophakic eyes [8]. Clinically, the disease may manifest by higher fragility of the lens capsule and zonular apparatus. After mydriatics application, a difficult dilatation of the pupil may occur (Figure 6) [1]. Pseudoexfoliation syndrome is also the most common identifiable cause of secondary open-angle glaucoma [4,7]. Due to the deposition of PEX material and pigment dispersion, there is a mechanical obstruction of the outflow of the ventricular fluid, which results in an increase in IOP with a possible pseudoexfoliation glaucoma [3]. This type of glaucoma has a higher level of IOP, faster progression and more difficult stabilisation of IOP with drug therapy than primary open-angle glaucoma [3,9]. Several studies have shown a significant reduction in IOP after cataract surgery in patients with glaucoma, averaging at 3-6 mmHg [3,10]. Cataract surgery in PEX syndrome is associated with a higher risk of perioperative and postoperative complications [3] (Table 1) [11]. The higher incidence of complications is due to a combination of poor mydriasis, increased fragility of the capsule and a weak zonular apparatus of the lens [1,3,9]. Compared to patients without PEX syndrome, a higher incidence of posterior capsule rupture, vitreous prolapse, vitreous dislocation or intraocular lens dislocation is reported [3,12]. Other risks include postoperative corneal decompensation for keratopathy and capsule phimosis [4]. Patients should be closely monitored in the postoperative period, due to longer postoperative healing, a demonstrably higher risk of prolonged inflammation, cystoid macular oedema, and IOP elevation [4,13]. Decentration, subluxation or dislocation of the intraocular lens



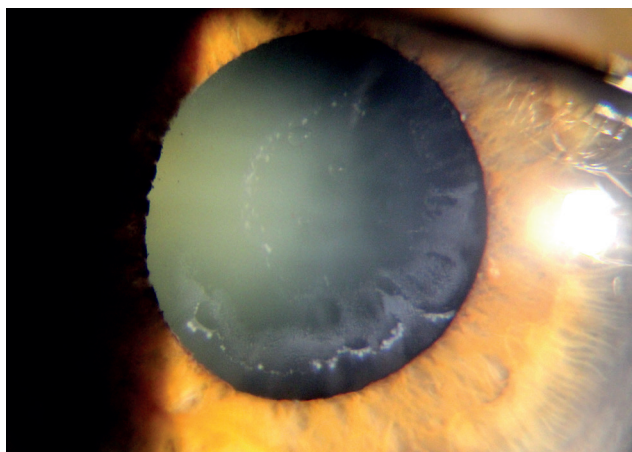
**Figure 3.** Fine fibres of pseudoexfoliation material can be easily overlooked on a slit lamp



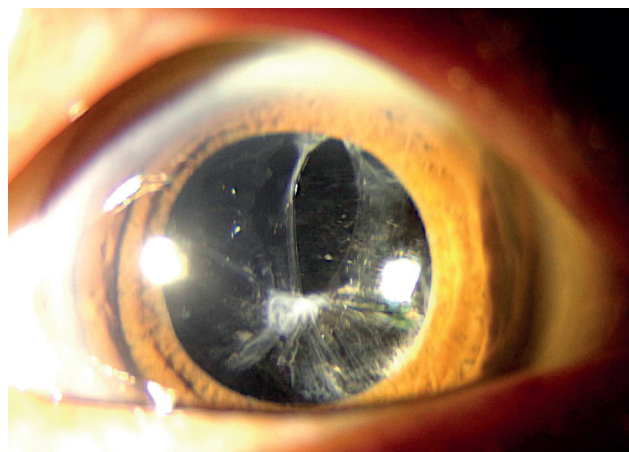
**Figure 4.** Concentric circles of pseudoexfoliation material on the surface of the anterior lens capsule



**Figure 5.** Sampaolesi line of angle during gonioscopy



**Figure 6.** Noticeable poor artificial mydriasis (eye of the same patient from Figure 2, before instillation of mydriatics)



**Figure 7.** Late complications after cataract surgery in pseudoexfoliation syndrome - anterior capsule phimosis with IOL decentration

can be included among the most common late complications, even after uncomplicated surgery (Figure 7) [14].

## METHODOLOGY AND DESIGN

This was a retrospective evaluation of the medical records of PEX syndrome patients who underwent cataract surgery at the Gemini Eye Clinic Ostrava-Hrusov. The study period was from November 2016 to April 2021. The evaluated parameters were the incidence of PEX syndrome, age and gender of patients, IOP before the surgery, pre-existing therapy of previously diagnosed secondary glaucoma and the occurrence of perioperative complications.

Prior to the planned surgery, each patient underwent an objective examination with an automated Auto Kerato-Refracto Tonometer with a pachymetry measurement (Tonoref III, NIDEK CO., LTD, Japan), endothelial cell microscope (CEM-530, NIDEK CO., LTD, Japan) and optical biometry (IOLMaster 500, Carl Zeiss Meditec, Germany).

Subjective measurements of uncorrected and corrected distance visual acuity were performed on projection optotypes. Near visual functions were also evaluated, using Jaeger's tables in myopic patients. Examination of the anterior and posterior segments was evaluated, using a slit lamp, including artificial mydriasis using an indirect lens. In indicated cases, corneal topography (Pentacam, OCULUS Optikgeräte GmbH, Germany), optical coherence tomography (OCT) (RTVue RT100, Optovue Inc., USA) and ultrasound B-scan of the eye (B-Scan Scanmate 8000, DGH Technology Inc., USA) were performed. To calculate the ideal intraocular lens (IOL), biometrics were measured optically by the IOLMaster in most patients. Ultrasound biometry (A-Scan Scanmate 8000, DGH Technology Inc., USA) was performed, when this technique was not feasible due to opacity of the optical media. The surgeries were performed using standard phacoemulsification procedures in combined local topical and intracameral anaesthesia and subsequent intraocular lens implanta-

**Table 1.** Possible clinical and surgical complications in pseudoexfoliation syndrome

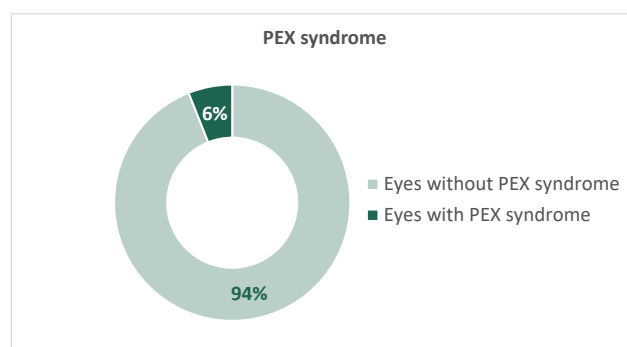
Tissue	Clinical complications	Surgical complications
Cornea	Endothelial decompensation Endothelial migration/proliferation	Endothelial decompensation
Trabecular meshwork	Intraocular hypertension Open-angle glaucoma	Postoperative intraocular pressure elevation
Iris	Poor mydriasis Pigment dispersion Iris rigidity Posterior synechiae Defect of blood-aqueous barrier	Poor surgical access Miosis Pupillary block Severe postoperative inflammation Posterior synechiae
Lens Zonules Ciliary body	Cataract Phacodonesis Lens subluxation/luxation Zonular instability Angle-closure glaucoma (due to pupillary/ciliary block)	Posterior capsular rupture Vitreous loss Intraocular lens decentration Capsular phimosis Secondary cataract Zonular dialysis
Posterior segment	Retinal vein occlusion	

tion. In the indicated cases, the procedure was supplemented by preventive or therapeutic implantation of the distension capsular ring. Postoperative medication of the operated eye involved local application of combined eye drops of tobramycin and dexamethasone 5 times a day during the first week, then only dexamethasone without preservatives for 20 days. From the first postoperative day, patients also applied a local non-steroidal anti-inflammatory drug to the eye for prophylaxis of cystoid macular oedema. The patient was then followed up by an external ophthalmologist.

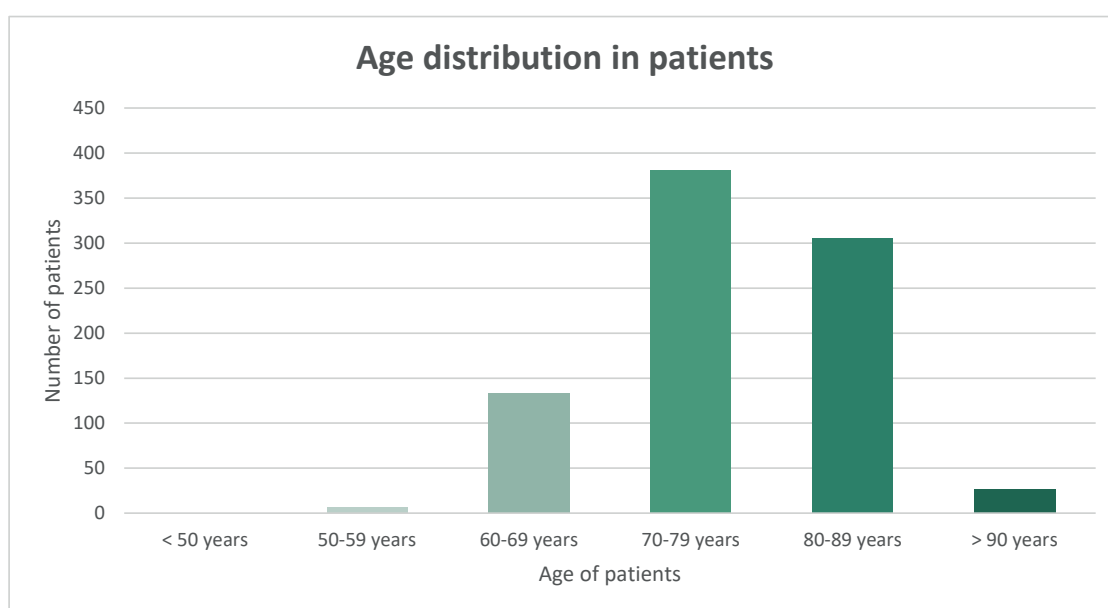
## RESULTS

In the study period of 4.5 years, out of the total number of 14 167 operated eyes with cataracts, 852 eyes of 689 patients were diagnosed with PEX syndrome, i.e. 6.0 %. (Gra-

ph 1). The mean age was 76.9 years, the median 77 years, range 54 to 100 years (Graph 2). The observed pathology was more common in women at a ratio of 1.84: 1 (552: 300)

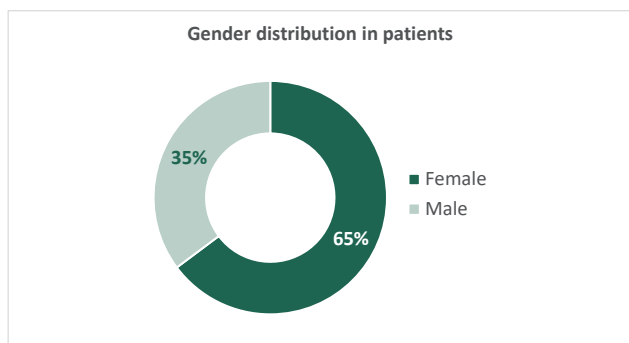


**Graph 1.** Incidence of pseudoexfoliation (PEX) syndrome in patients before planned cataract surgery

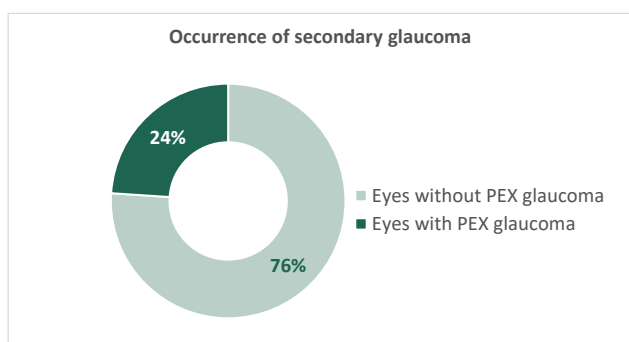


**Graph 2.** Age distribution in patients with pseudoexfoliation syndrome

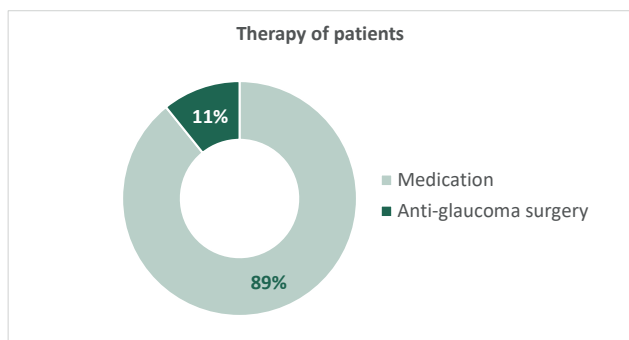




**Graph 3.** Gender distribution in patients with pseudoexfoliation syndrome



**Graph 4.** Occurrence of secondary glaucoma in patients with pseudoexfoliation (PEX) syndrome



**Graph 5.** Therapy of patients with pseudoexfoliation glaucoma

(Graph 3). Elevated IOP, above 21 mmHg, was recorded in 118 eyes. In 14 of them, IOP reached values over 30 mmHg. According to the increased IOP, local or general antiglaucoma drugs (brinzolamide, timolol or acetazolamide) were applied before the procedure. Diagnosed and long-term treated secondary glaucoma was confirmed by 153 patients (204 eyes) (Graph 4), of which 22 eyes underwent antiglaucoma laser (19 eyes) and / or surgery (5 eyes) in the anamnesis – laser iridotomy (LIRI), selective laser trabeculoplasty (SLT), argon laser trabeculoplasty (ALT) or surgical trabeculectomy with iridectomy (Graph 5). Perioperatively, in 231 eyes we recorded the following pathological findings accompanying the occurrence of PEX syndrome – most often poor artificial mydriasis (189 eyes), subluxation of the lens (31 eyes) or zonular fragility (17 eyes). To reduce

the risk of perioperative and postoperative complications, implantation of a capsular tension ring was indicated in 20 eyes. Complications during the procedure occurred in 11 eyes, of which 8 eyes were diagnosed with advanced cataract (3x brunescens, 1x nigra, 3x mature and 1x intumescent cataract). The most common was zonulolysis, with eventual vitreous prolapse, which required anterior vitrectomy in 5 cases. We recorded a rupture of the posterior capsule of the lens twice, and in one patient dislocation of the lens quadrant into the vitreous space, necessitating a subsequent pars plana vitrectomy. In 8 cases, we implanted an anterior chamber artificial lens in the patient's eye, and in one case we implanted a posterior chamber intraocular lens with scleral fixation.

In the early postoperative period, one patient developed secondary glaucoma dolorosa, for which an anterior chamber intraocular lens was extracted at another workplace. Subsequently, this aphakic patient was indicated for secondary implantation of a posterior chamber intraocular lens with scleral fixation, but did not attend the procedure.

## DISCUSSION

Pseudoexfoliation syndrome is a systemic disease with varying frequency, depending on latitude. It is most often described in the Scandinavian countries. A population-based study evaluating the prevalence of PEX syndrome in people over the age of 66 reports that one in four individuals is affected out of a total of 339 participants [15]. At the end of the 21-year follow-up period, the incidence of PEX syndrome observed rose from 23% in 66 year-olds to 61% at the age of 87 [16]. Ariga states in his article that the incidence of PEX syndrome varies, depending on the population, between 6-10% [17], which corresponds to the results among our patients (6.0%). A retrospective study by Vazquez-Ferreiro et al., monitoring the incidence of PEX syndrome in patients undergoing cataract surgery, reports 120 eyes affected out of a total of 681 operated eyes (17.6%) [18]. However, comparable work evaluating the incidence of PEX syndrome and related secondary glaucoma in terms of file size was not found. While the results of European studies report a more frequent presence of unilateral disability, American studies tend to report a higher incidence of bilateral PEX syndrome [19]. However, our patient sample showed a ratio of almost 1:1 (423: 429). Due to the systemic nature of the disease, a thorough observation of the second eye, which is still macroscopically intact, is necessary even in the presence of unilateral PEX syndrome. This is especially important for the possible early detection of secondary glaucoma associated with this pathognomonic unit. This glaucoma was first described in 1917 by Lindberg in Finland [20]. Kuchynka states that glaucoma occurs in up to 20% of patients with PEX syndrome [1]. Obuchowska et al. in their work described glaucoma in 28 of 82 eyes with PEX syndrome (34.1%) [21]. Potocky observed an association

with secondary glaucoma among his operated patients in even 39.1 % of cases out of a total of 2916 eyes [22]. In our cohort, patients reported diagnosed glaucoma in 23.94% of eyes, which corresponds to the range reported by Kanski (15-30%) [4]. However, all these studies involve smaller cohorts of patients compared to our cohort. The cataractogenic effect of the pseudoexfoliation material is also described, but the exact pathophysiology of this association is not yet completely clear [11]. The Reykjavik eye study followed up 1 045 patients with PEX syndrome over a 12-year period and revealed a higher probability of indicating cataract surgery in these patients [23]. Similarly, other research with a follow-up period of 30 years confirmed PEX syndrome as a strong predictive factor of cataract surgery, compared to subjects without diagnosed PEX syndrome [24]. Numerous studies have shown a positive effect of phacoemulsification on postoperative intraocular pressure and deepening of the anterior chamber of the eye [10,25,26,27]. Improving the anatomical parameters of the anterior segment of the eye after phacoemulsification can have a major impact on patients with pseudoexfoliation glaucoma. PEX syndrome is not only associated with an increased risk of developing cataracts, but also with an increased risk of these complications during the procedure and in the postoperative period. To reduce possible perioperative complications, it is advisable to minimise the zonular stress when manipulating the nucleus and cortex. For example, a larger capsulorhexis, which is also a prophylaxis of the development of capsular phimosis in the postoperative period, can help us to do this. In the case of a small pupil, the use of viscomydriasis or the establishment of iris hooks is appropriate. Another mechanical helper used to stabilise the capsular bag is CTR [28, 29]. The question remains whether CTR should

be implanted prophylactically in the other eye, which is still without signs of PEX syndrome [30, 31]. In our experience, we do not agree with this view, because in most of our patients a distension ring was not necessary. With consistent preoperative preparation, perioperative and postoperative care and, at the same time, thanks to the progress of the surgical techniques, instruments and materials used, the postoperative result in patients with PEX syndrome is almost comparable to the healthy population [11].

## CONCLUSION

PEX syndrome and glaucoma are relatively common diseases that can complicate the lives of patients and eye surgeons. The incidence of PEX syndrome in our cataract patients was 6 %. Proper diagnosis of this disease is important, not only for the possible occurrence of numerous complications during and after cataract surgery, but also for the possible presence of secondary glaucoma. It also aims to detect possible involvement of the contralateral eye. In addition, due to the involvement of practically all tissues in the body, the patient is endangered by numerous, especially vascular comorbidities. For these reasons, we find it appropriate that these patients are observed by other healthcare specialists.

In our experience, early indication for cataract surgery for a lower degree of zonular fragility and a softer lens core is important, which results from the number of perioperative complications we have noted. These occurred in 72% of advanced forms of lens opacity. In addition, lower levels of proinflammatory pseudoexfoliation material occur in the anterior segment of the eye in the early stages, which may have a beneficial effect on postoperative healing.

## REFERENCES

- Kuchynka P. Oční lékařství. 2. vyd. Praha: Grada; 2016. 936. Czech.
- Tony Realini, M.D. A new gene for pseudoexfoliation. EyeWorld. Retrieved 2011-08-05.
- Samková K. Sekundární glaukomy. 2. vyd. Praha: Mladá fronta a.s.; 2018. 200. Czech.
- Salmon JF, Kanski JJ. Kanski's clinical ophthalmology: a systematic approach. 9. vyd. UK: Elsevier; 2020. 941.
- Siordia JA, Franco J, Golden TR, Dar B. Ocular Pseudoexfoliation Syndrome Linkage to Cardiovascular Disease. Curr Cardiol Rep. 2016 Jul;18(7):61. doi: 10.1007/s11886-016-0738-5
- Benda T. Výskyt kardiovaskulárních onemocnění u pacientů s pseudoexfoliativním syndromem a pseudoexfoliativním glaukomem [Cardiovascular Diseases Occurrence in Patients with Pseudoexfoliative Syndrome and Pseudoexfoliative Glaucoma]. Cesk Slov Oftalmol. 2011;67 (1):12-15. Czech. Available from: <https://www.prolekare.cz/casopisy/ceska-slovenska-ofthalmologie/2011-1/vyskyt-kardiovaskularnich-onemocneni-u-pacientu-s-pseudoexfoliativnim-syndromem-a-pseudoexfoliativnim-glaukomem-34775>
- Schweitzer C. Syndrome pseudo-exfoliatif et glaucome exfoliatif. Journal Français d'Ophtalmologie, Volume 41, Issue 1, 2018; 78-90. ISSN 0181-5512.
- Sternfeld A, Luski M, Sella R et al. Diagnosis of Pseudoexfoliation Syndrome in Pseudophakic Patients. Ophthalmic Res. 2021;64(1):28-33. doi: 10.1159/000508336. Epub 2020 Apr 30
- Rozsival P et al. Oční lékařství. 1. vyd. Praha: Galén; 2006. 373. Czech.
- Ramezani F, Nazarian M, Rezaei L. Intraocular pressure changes after phacoemulsification in pseudoexfoliation versus healthy eyes. BMC Ophthalmol. 2021 May 6;21(1):198. doi: 10.1186/s12886-021-01970-y
- Tekin K, Inanc M, Elgin U. Monitoring and management of the patient with pseudoexfoliation syndrome: current perspectives. Clin Ophthalmol. 2019 March;13:453-464. doi:10.2147/OPHTH.S181444
- Sangal N, Chen TC. Cataract surgery in pseudoexfoliation syndrome. Semin Ophthalmol. 2014 Sep-Nov;29(5-6):403-408. doi: 10.3109/08820538.2014.959189
- Heissigerová J a kol. Oftalmologie. 1. vyd. Praha: Maxdorf; 2018. 380. Czech.
- Masket S, Osher RH. Late complications with intraocular lens dislocation after capsulorhexis in pseudoexfoliation syndrome. J Cataract Refract Surg. 2002 Aug;28(8):1481-1484. doi: 10.1016/s0886-3350(01)01267-6. PMID: 12160826
- Ariga M, Nivean M, Utkarsha P. Pseudoexfoliation Syndrome. J Curr Glaucoma Pract. 2013;7(3):118-120. doi:10.5005/jp-journals-10008-1148
- Vazquez-Ferreiro P, Carrera-Hueso FJ, Barreiro-Rodriguez L, Diaz-Rey M, Jornet JEP. Prevalence of cataract complications in patients with pseudoexfoliation syndrome in Northwestern Spain.

- Arq Bras Oftalmol. 2019 Sep 12;82(6):495-500. doi: 10.5935/0004-2749.20190095
17. Aström S, Lindén C. Incidence and prevalence of pseudoexfoliation and open-angle glaucoma in northern Sweden: I. Baseline report. *Acta Ophthalmol Scand.* 2007 Dec;85(8):828-831. doi: 10.1111/j.1600-0420.2007.00992.x. Epub 2007 Nov 6
  18. Aström S, Stenlund H, Lindén C. Incidence and prevalence of pseudoexfoliations and open-angle glaucoma in northern Sweden: II. Results after 21 years of follow-up. *Acta Ophthalmol Scand.* 2007 Dec;85(8):832-837. doi: 10.1111/j.1600-0420.2007.00980.x. Epub 2007 Nov 6
  19. Plateroti P, Plateroti AM, Abdolrahimzadeh S, Scuderi G. Pseudoexfoliation Syndrome and Pseudoexfoliation Glaucoma: A Review of the Literature with Updates on Surgical Management. *J Ophthalmol.* 2015;2015:370-371. doi: 10.1155/2015/370371. Epub 2015 Oct 29
  20. Yanoff M, Duker JS. *Ophthalmology*. 3rd. ed. Mosby Elsevier inc.; 2009. 1528.
  21. Obuchowska I, Bryl-Przybylska A, Mariak Z. Zespół pseudoeksfoliacji u pacjentów wyznaczanych do operacji zaćmy [Pseudoexfoliation syndrome in patients scheduled for cataract surgery]. *Klin Oczna.* 2006;108(10-12):397-400. Polish.
  22. Potocký M. Pseudoexfoliatívny syndróm a jeho význam pre operáciu sivého zákalu [Pseudoexfoliative Syndrome and Its Importance for Operation on Cataract]. *Cesk Slov Oftalmol.* 2003;59(6):422-432. Slovak. Available from: <https://www.prolekare.cz/casopisy/ceska-slovenska-ofthalmologie/2003-6/pseudoexfoliativny-syndrom-a-jeho-vyznam-pre-operaciu-siveho-zakalu-27726>
  23. Arnarsson A, Sasaki H, Jonasson F. Twelve-year incidence of exfoliation syndrome in the Reykjavik eye study. *Acta Ophthalmol.* 2013;91(2):157-162.
  24. Ekström C, Botling Taube A. Pseudoexfoliation and cataract surgery: a population-based 30-year follow-up study. *Acta Ophthalmol.* 2015;93(8):774-777.
  25. Kristianslund O, Østern AE, Råen M, Sandvik GF, Drolsum L. Does cataract surgery reduce the long-term risk of glaucoma in eyes with pseudoexfoliation syndrome? *Acta Ophthalmol.* 2016 May;94(3):261-265. doi: 10.1111/aos.12945. Epub 2016 Jan 9
  26. Mierzejewski A, Eliks I, Kałuzny B, Zygułska M, Harasimowicz B, Kałuzny JJ. Cataract phacoemulsification and intraocular pressure in glaucoma patients. *Klin Oczna.* 2008;110(1-3):11-17.
  27. Bhandari S, Pandyal I, Khanal SP, Thapa SS. Effect of phacoemulsification surgery on various parameters in patients with glaucoma. *Nepal J Ophthalmol.* 2014 Jan;6(11):46-55. doi: 10.3126/nepjoph.v6i1.10772
  28. Calafati J, Tam DY, Ahmed IK. Pseudoexfoliation syndrome in cataract surgery. *Eye Net* 2009;13:37-39.
  29. Kaštelan S, Tomić M, Kordić R, Kalauz M and Salopek-Rabatić J. Cataract Surgery in Eyes with Pseudoexfoliation Syndrome. *J Clinic Experiment Ophthalmol* 51-009. 2013.
  30. Moreno-Montañés J, Rodríguez-Conde R. Capsular tension ring in eyes with pseudoexfoliation. *J Cataract Refract Surg.* 2002 Dec;28(12):2241-2242. doi: 10.1016/s0886-3350(02)01901-6
  31. Scherer M, Bertelmann E, Rieck P. Late spontaneous in-the-bag intraocular lens and capsular tension ring dislocation in pseudoexfoliation syndrome. *J Cataract Refract Surg.* 2006 Apr;32(4):672-675. doi: 10.1016/j.jcrs.2006.01.041